

CME

ACG Clinical Guideline: Liver Disease and Pregnancy

Tram T. Tran, MD, FACP, FAASLD¹, Joseph Ahn, MD, MS, FACP² and Nancy S. Reau, MD, FAASLD, FAGA³

Consultation for liver disease in pregnant women is a common and oftentimes vexing clinical consultation for the gastroenterologist. The challenge lies in the need to consider the safety of both the expectant mother and the unborn fetus in the clinical management decisions. This practice guideline provides an evidence-based approach to common diagnostic and treatment challenges of liver disease in pregnant women.

Am J Gastroenterol 2016; 111:176–194; doi:10.1038/ajg.2015.430; published online 2 February 2016

Management of pregnant women with liver disease is a common clinical scenario, and one that can be challenging given the need to consider not only the expectant mother, but also the unborn fetus in treatment decisions. The purpose of this guideline is to provide a review of the diagnostic and treatment challenges of managing liver disease in pregnant women. The evidence behind approaches to diagnosis and treatment of liver disease in pregnant women are assessed to provide management recommendations.

These recommendations are based on the following: (i) a search and review with analysis of the recently published world literature on the topic using Medline search from 1946 to present, EMBASE 1988 to present, and SCOPUS from 1980 to present using the search terms listed in the **Appendix**. (ii) Guideline policies of the ACG. Intended for use by physicians and allied health professionals, these recommendations suggest preferred approaches to the diagnostic, therapeutic, and preventive aspects of care. These are intended to be flexible and adjustable for individual patients (1).

To best characterize the evidence cited in support of the recommendations, the ACG practice guidelines have implemented the use of the Grading of Recommendation Assessment, Development, and Evaluation (GRADE) system. The strength of recommendations in the GRADE system is classified as strong (when the positive effects of an intervention or recommendation clearly are greater than the negative effects) or conditional (when there is uncertainty regarding the positive vs. negative aspects of the recommendation) (2). The quality of evidence supporting strong or conditional recommendations is designated by one of four levels: high (suggesting that further research is unlikely to change the authors' confidence in the estimate of effect), moderate (further research would be anticipated to have an impact on the confidence in the estimate of effect), low quality (further research would be anticipated to have an important impact on the confidence in the estimate of the effect and also likely change the estimate), or very low quality (the estimate of effect is uncertain) (2).

To determine the level of evidence, the results from the selected papers with the greatest level of evidence were extrapolated and utilized in the GRADE program (<http://www.gradepro.org>). A summary of the recommendations are outlined in **Table 1**.

EVALUATION OF THE PREGNANT PATIENT WITH ABNORMAL LIVER ENZYMES

Recommendations:

1. A pregnant patient presenting with abnormal liver tests should undergo standard workup as with any non-pregnant individual (strong recommendation, very low level of evidence).

The basis for the workup of abnormal liver tests in a pregnant woman should be predicated on understanding the normal physiological changes observed during pregnancy.

The incidence of abnormal liver tests in pregnant women is ~3–5%, even in this relatively young and healthy population. Some liver test results, which would otherwise suggest liver or biliary dysfunction in the non-pregnant individual may in fact be “normal” in the pregnant woman. Conversely, abnormal test results should be appropriately evaluated as some diseases newly diagnosed in pregnancy may require more immediate intervention for the mother or the neonate (e.g., herpes hepatitis, hepatitis B; **Table 2**) Generally, the majority of liver tests remain in the normal range in pregnancy except those produced by the placenta (alkaline phosphatase, alpha-fetoprotein) or impacted as a result of hemodilution (albumin, hemoglobin). Of note, during pregnancy, cardiac output is increased by 40–45% with substantive increases to the renal, uterine, and skin systems. However, the liver blood flow shows little change during pregnancy, suggesting a relative decrease of total percent of cardiac output (3). Any abnormality seen in transaminases and bilirubin needs further evaluation (**Figure 1**).

¹Department of Medicine, Liver Transplant, Cedars Sinai Medical Center, Los Angeles, California, USA; ²Department of Medicine, Oregon Health & Science University, Portland, Oregon, USA and ³Department of Medicine, Rush University, Chicago, Illinois, USA. **Correspondence:** Tram T. Tran, MD, FACP, FAASLD, Department of Medicine, Liver Transplant, Cedars Sinai Medical Center, Los Angeles, California 90048, USA. E-mail: TranT@cshs.org

Received 7 September 2015; accepted 17 December 2015

Table 1. Recommendation statements*Initial evaluation of pregnant patient*

A pregnant patient presenting with abnormal liver tests should undergo standard workup as with any non-pregnant individual (strong recommendation, very low level of evidence).

Imaging in pregnancy

Ultrasound is safe and the preferred imaging modality used in assessment of abnormal liver tests suggestive of biliary tract disease (strong recommendation, low level of evidence).

Magnetic resonance imaging without gadolinium can be used in the second and third trimester (conditional recommendation, low level of evidence).

Computed tomography scans carry a risk of teratogenesis and childhood hematologic malignancies but may be used judiciously with minimized radiation protocols (2–5 rads; conditional recommendation, very low level of evidence).

Endoscopy in pregnancy

Endoscopy is safe in pregnancy but should be deferred until the second trimester if possible (strong recommendation, low level of evidence).

Meperidine and propofol can be used for endoscopic sedation (strong recommendation, moderate level of evidence).

Management of biliary disease in pregnancy

ERCP can be performed when indicated for pregnant women presenting with biliary disease that strongly necessitates intervention such as biliary pancreatitis, symptomatic choledocholithiasis, and/or cholangitis. Minimizing fetal exposure to fluoroscopy is imperative (strong recommendation, low level of evidence).

Symptomatic cholecystitis should be managed with early surgical intervention with laparoscopic cholecystectomy (strong recommendation, low level of evidence).

Liver masses in pregnancy

Asymptomatic hemangioma and focal nodular hyperplasia do not need routine imaging or surveillance during pregnancy (strong recommendation, very low level evidence).

Hepatic adenomas should be monitored with ultrasound during pregnancy for growth. Patients with large adenomas (>5 cm) should be referred for resection prior to pregnancy (strong recommendation, low level of evidence).

Hepatitis B in pregnancy

Active–passive immunoprophylaxis with hepatitis B immunoglobulin and the HBV vaccination series should be administered to all infants born to HBV-infected mothers to prevent perinatal transmission (strong recommendation, low level of evidence).

Women chronically infected with HBV and high viral load (>10⁶ log copies/ml (200,000 IU/ml) and higher) should be offered antiviral medication with tenofovir or telbivudine in the third trimester to reduce perinatal transmission of HBV (strong recommendation, low level of evidence).

C-section should not be performed electively in HBV-positive mothers to prevent fetal infection (strong recommendation, very low level of evidence).

Women chronically infected with HBV should be allowed to breastfeed as recommended for infant health (strong recommendation, very low level of evidence).

Hepatitis C in pregnancy

All pregnant women with risk factors for HCV should be screened with anti-HCV antibody. Screening should not be performed in women without risk factors for HCV acquisition (strong recommendation, low level of evidence).

Invasive procedures (e.g., amniocentesis, invasive fetal monitoring) should be minimized in infected mothers and their fetus to prevent vertical transmission of hepatitis C (strong recommendation, very low level of evidence).

C-section should not be performed electively in HCV-positive mothers to prevent fetal infection (strong recommendation, very low level of evidence).

Women chronically infected with HCV should be allowed to breastfeed as indicated for infant health (strong recommendation, very low level of evidence).

Hepatitis C therapy should not be offered to pregnant women to either treat HCV or decrease the risk for vertical transmission (strong recommendation, very low level of evidence).

Liver disease unique to pregnancy

The treatment of hyperemesis gravidarum is supportive and may require hospitalization (strong recommendation, very low level of evidence).

Intrahepatic cholestasis of pregnancy

Owing to increased risk of fetal complications with IHCP, early delivery at 37 weeks is recommended (strong recommendation, very low level of evidence).

Ursodeoxycholic acid, should be given at 10–15 mg/kg, to women with IHCP for symptomatic improvement (strong recommendation, moderate level of evidence).

Preeclampsia and eclampsia

Preeclampsia with hepatic involvement elevates the diagnosis to severe preeclampsia. After 36 weeks, women with severe preeclampsia should be delivered promptly to limit maternal and fetal complications (strong recommendation, very low level of evidence).

HELLP syndrome

HELLP syndrome should be managed by prompt delivery, especially after 34 weeks gestation (strong recommendation, very low level of evidence).

Table 1 continued on following page

Table 1. Continued

Platelet transfusion to 40,000–50,000 cells/ μ l should be considered before delivery, especially if cesarean section is likely (conditional recommendation, very low level of evidence).
Acute fatty liver disease of pregnancy
Women with AFLP should be delivered promptly; expectant management is not appropriate (strong recommendation, very low level of evidence).
All women with AFLP and their children should have molecular testing for long-chain 3-hydroxyacyl-CoA dehydrogenase (conditional recommendation, moderate level of evidence).
The offspring of mothers affected by AFLP should be monitored carefully for manifestations of deficiency of long-chain 3-hydroxyacyl-coenzyme A dehydrogenase including hypoketotic hypoglycemia and fatty liver (conditional recommendation, very low level of evidence).
Hepatitis A, hepatitis E, herpes simplex virus
Pregnant women presenting with acute hepatitis should be tested for common etiologies of acute liver injury including viral hepatitis HAV, HBV, HEV, and HSV (strong recommendation, very low level of evidence).
Pregnant women with acute hepatitis suspected from HSV should be initiated on acyclovir (strong recommendation, very low level of evidence).
Other chronic liver disease
Pregnant women with AIH should be continued on their treatment with corticosteroids and/or AZA (strong recommendation, very low level of evidence).
Pregnant women with PBC should be continued on their treatment with UDCA (strong recommendation, very low level of evidence).
Pregnant women with WD should be continued, with dose reduction if possible, on their treatment with penicillamine, trientine, or zinc (strong recommendation, very low level of evidence).
Pregnant women with suspected portal hypertension should undergo screening with upper endoscopy for esophageal varices in the second trimester (strong recommendation, low level of evidence).
Pregnant women who are found to have large esophageal varices should be treated with beta-blockers and/or band ligation (conditional recommendation, very low level of evidence).
Pregnant women with a history of liver transplantation should continue their immunosuppression except for mycophenolic acid (strong recommendation, moderate level of evidence).
AFLP, acute fatty liver disease of pregnancy; AIH, autoimmune hepatitis; AZA, azathioprine; ERCP, endoscopic retrograde cholangiopancreatography; HAV, hepatitis A virus; HBV, hepatitis B virus; HCV, hepatitis C virus; HELLP, hemolysis, elevated liver enzymes, low platelets; HEV, hepatitis E virus; HSV, herpes simplex virus; IHCP, intrahepatic cholestasis of pregnancy; PBC, primary biliary cirrhosis; WD, Wilson's disease.

The first step in assessing a woman presenting at any stage of pregnancy with abnormal liver tests should be the same as with any non-pregnant patient. A complete history, physical exam, and standard serological workup should be performed as indicated by the clinical presentation. Initial evaluation of these patients can be categorized into two general groups: (i) pre-existing and coincidental, not related to pregnancy, or (ii) related to the pregnancy itself.

IMAGING

Recommendations:

2. Ultrasound is safe and the preferred imaging modality used in assessment of abnormal liver tests suggestive of biliary tract disease (strong recommendation, low level of evidence).
3. Magnetic resonance imaging (MRI) without gadolinium can be used in the second and third trimester (conditional recommendation, low level of evidence).
4. Computed tomography (CT) scans carry a risk of teratogenesis and childhood hematologic malignancies but may be used judiciously with minimized radiation protocols (2–5 rads) (conditional recommendation, very low level of evidence).

Table 2. Normal physiologic changes in lab tests during pregnancy

Test	Change in pregnancy
AST/ALT	↔
Bilirubin	↔
Prothrombin/INR	↔
Albumin	↓
Alkaline phosphatase	↑
Hemoglobin	↓
Alpha fetoprotein	↑
5' nucleotidase	↔
Gamma glutamyl transpeptidase	↔
ALT, alanine transaminase; AST, aspartate transaminase; INR, international normalized ratio.	

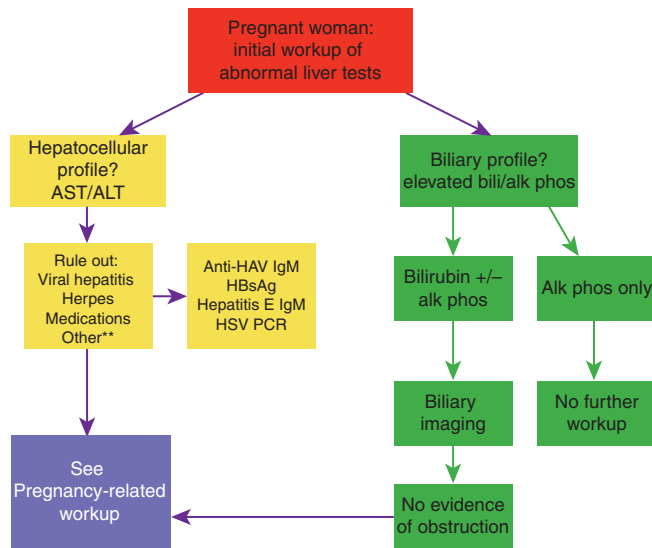


Figure 1. Workup of abnormal liver test in pregnant woman. **Other differential diagnosis to consider if clinically appropriate: AIH, Wilson disease.

It may be clinically appropriate and necessary during pregnancy to image the liver, hepatic vasculature, or biliary system. Any pregnant woman presenting with abnormal aminotransferases or jaundice should first undergo an abdominal ultrasound. Ultrasound, with or without Doppler imaging, as it uses sound waves and not ionizing radiation, has never been shown to have any adverse fetal effects (4,5). Therefore, there are no contraindications to ultrasound in pregnancy and it should be used as the imaging modality of choice.

Teratogenicity has been clearly established, with large doses of radiation >100 rad, linked in humans to growth restriction and microcephaly, among other adverse effects. The greatest exposure risk is at 8–15 weeks of gestation. Fetal risks of anomalies and growth restriction appear not to be increased if the exposure is <5 rad. Fetal exposure for commonly used gastroenterology imaging ranges from 100 mrad, for a single abdominal film, to 2–4 rad, for a barium enema or small bowel series, to 3.5 rad for a CT scan of the abdomen (6,7). If ultrasonography is indeterminate and further imaging is necessary, judicious use of CT or MRI without gadolinium may be considered for the expeditious diagnosis of an acute presentation. Oral and intravascular contrast agents used for CT contain derivatives of iodine which do not appear teratogenic in animal studies. However, neonatal hypothyroidism has been associated with iodinated contrast agent exposure during pregnancy (8). Gadolinium is not recommended as it crosses the placenta and is excreted by the fetal kidneys into the amniotic fluid where it can remain for long periods, exposing the fetal pulmonary and gastrointestinal systems to potential injury. Animal studies have also reported spontaneous abortion, skeletal abnormalities, and visceral abnormalities with high doses of gadolinium (4).

Fortunately, the necessity of liver biopsy for diagnosis of disease in pregnancy is uncommon as most etiologies can be determined in this population by biochemical, serological, and clinical parameters. However, if required, percutaneous liver biopsy can be performed safely. Transjugular liver biopsy can also be performed but carries some limited radiation exposure of 0.05–0.1 rad (9,10).

SAFETY OF ENDOSCOPY IN PREGNANCY

Recommendations:

- Endoscopy is safe in pregnancy but should be deferred until the second trimester if possible (strong recommendation, low level of evidence).
- Meperidine and propofol can be used for endoscopic sedation (strong recommendation, moderate level of evidence).

Although clinical studies on the safety and effectiveness of endoscopy for the pregnant patient have been limited, endoscopy can be safe and effective if careful assessment of the risks, benefits, and clinical rationale is performed. One of the most important clinical issues in endoscopy of the pregnant patient is to ensure hemodynamic stability and oxygenation. Over-sedation, resulting in hypotension or hypoxia, or positioning that compresses the inferior vena cava can lead to decreased uterine blood flow and fetal hypoxia. Thus, the patient should be positioned in the left lateral position to avoid vascular compression and aggressively managed with respect to intravenous hydration (11). Other concerns include teratogenicity of medications and radiation exposure.

There are currently no FDA pregnancy category A medications available for the management of sedation during endoscopy. The benzodiazepine class of sedatives (FDA category D) should be avoided in pregnancy owing to known congenital malformations (12,13). One of the most commonly used sedation medications during pregnancy is meperidine, an opiate analgesic, which has more recently been replaced by shorter acting agents, such as propofol, with lower risk for respiratory depression and seizures. Meperidine crosses the placenta and is converted to a long-lasting normeperidine, so repeated or prolonged meperidine administration should be avoided late in pregnancy or at term, as meperidine is an FDA pregnancy category C (14,15).

Propofol is an FDA pregnancy category B anesthetic which is very short acting with a rapid recovery period, which is of significant benefit in the case of a pregnant patient. If propofol is used, an anesthesiologist should monitor respiratory function closely.

Multidisciplinary consultation with obstetrics is essential, and further anesthesia and surgical opinion may be helpful in approaching endoscopy. Deferring endoscopy until the second trimester is recommended when possible and special considerations for maternal–fetal monitoring, and aspiration precautions should be undertaken.

MANAGEMENT OF BILIARY DISEASE IN PREGNANCY

Recommendations:

7. ERCP can be performed when indicated for pregnant women presenting with biliary disease that strongly necessitates intervention such as biliary pancreatitis, symptomatic choledocholithiasis, and/or cholangitis. Minimizing fetal exposure to fluoroscopy is imperative (strong recommendation, low level of evidence).
8. Symptomatic cholecystitis should be managed with early surgical intervention with laparoscopic cholecystectomy (strong recommendation, low level of evidence).

Cholelithiasis is common in pregnancy owing to the increased estrogen levels, causing cholesterol supersaturation and increased gallstone formation. Cholecystitis is the second most common surgical condition in pregnancy and occurs in ~1 in 1,600 to 1 in 10,000 pregnancies. The incidence of cholelithiasis in pregnant women is 3.5% (10). In the setting of laboratory testing indicating a possible biliary etiology, the first step in diagnosis should be an abdominal ultrasound, which has 95% sensitivity for the diagnosis of gallstones. Biliary pancreatitis, symptomatic choledocholithiasis, and cholangitis may have poor fetal outcomes without intervention. ERCP safety has been reported in multiple series, with some reports of increased pancreatitis risk (16%). Reducing fetal exposure to radiation should be attempted by limiting fluoroscopy time, external fetal shielding, and adjusting the patient position (16–20).

Symptomatic cholecystitis had been previously managed conservatively, but more recent data suggests high rates of recurrent symptoms (40–90%), increased rates of hospitalizations, preterm labor and deliveries, and spontaneous abortions when intervention is deferred. The development of gallstone pancreatitis portends a high rate (10–60%) of fetal demise. Thus, early surgical intervention with laparoscopic cholecystectomy after ERCP is preferred (21,22). One recent study of 9,714 women who underwent cholecystectomy while pregnant, reported longer length of stay than non-pregnant women and maternal and fetal complication rates of 4.3% and 5.8%, respectively (23).

LIVER MASSES IN PREGNANCY

Recommendations:

9. Asymptomatic hemangioma and focal nodular hyperplasia do not need routine imaging or surveillance during pregnancy (strong recommendation, very low level evidence).
10. Hepatic adenomas should be monitored with ultrasound during pregnancy for growth. Patients with large adenomas (>5 cm) should be referred for resection before pregnancy (strong recommendation, low level of evidence).

Fortunately, liver masses discovered during pregnancy are rare and most commonly are benign. Hemangiomas, focal nodular hyperplasia, and hepatic adenoma may be discovered on routine imaging with ultrasound. Further characterization with MRI or

tagged RBC scan may be needed. Patients presenting with large hemangiomas can present asymptotically or with pain and abdominal distension. Spontaneous rupture of hemangiomas is exceedingly rare, even with large lesions, thus routine symptomatic follow-up and standard vaginal delivery is safe. Focal nodular hyperplasia is found in 3% of the population, and multiple case series in pregnant women reported routine pregnancies with good clinical outcomes. Hepatic adenomas have a higher risk of growth during pregnancy owing to hormonal stimulation, and ultrasound monitoring should be done during pregnancy. If a diagnosis of large hepatic adenoma is made in a young woman of child-bearing age, appropriate consultation and follow-up should be performed. If a hepatic adenoma is larger than 5 cm or rapid growth is noted, surgical or radiological intervention should be recommended before pregnancy. The ACG Clinical Guideline on the diagnosis and management of focal liver lesions further details this topic (24–27).

LIVER DISEASES UNIQUE TO PREGNANCY

Recommendations:

11. The treatment of hyperemesis gravidarum (HG) is supportive and may require hospitalization (strong recommendation, very low level of evidence).
12. Because of increased risk of fetal complications with intrahepatic cholestasis of pregnancy (IHCP), early delivery at 37 weeks is recommended (strong recommendation, very low level of evidence).
13. Ursodeoxycholic acid (UDCA) should be given at 10–15 mg/kg to women with IHCP for symptomatic improvement (strong recommendation, moderate level of evidence).
14. Preeclampsia with hepatic involvement elevates the diagnosis to severe preeclampsia. After 36 weeks, women with severe preeclampsia should be delivered promptly to limit maternal and fetal complications (strong recommendation, very low level of evidence).
15. Hemolysis, elevated liver enzymes, and low platelets (HELLP) syndrome should be managed by prompt delivery, especially after 34 weeks gestation (strong recommendation, very low level of evidence).
16. Platelet transfusion to 40,000–50,000 cells/ μ l should be considered before delivery, especially if cesarean section is likely (conditional recommendation, very low level of evidence).
17. Women with acute fatty liver disease of pregnancy (AFLP) should be delivered promptly; expectant management is not appropriate (strong recommendation, very low level of evidence).
18. All women with AFLP and their children should have molecular testing for long-chain 3-hydroxyacyl-CoA dehydrogenase (LCHAD; conditional recommendation, moderate level of evidence).
19. The offspring of mothers affected by AFLP should be monitored carefully for manifestations of deficiency of LCHAD including hypoketotic hypoglycemia and fatty liver (conditional recommendation, very low level of evidence).

Table 3. Liver diseases unique to pregnancy

Disorder	Trimester	Management
HG	First through 20 weeks	Supportive management
IHCP	Second/third	Ursodeoxycholic acid 10–15 mg/kg Early delivery at 37 weeks
AFLP	Third	Women with AFLP should be delivered promptly Infant should be monitored for manifestations of deficiency of long-chain 3-hydroxyacyl-coenzyme A dehydrogenase including hypoketotic hypoglycemia and fatty liver
Eclampsia, preeclampsia	After 20 weeks	After 36 weeks, women with severe preeclampsia should be delivered promptly
HELLP	After 22 weeks	Delivery after 34 weeks Platelet transfusion to 40,000–50,000 cells/ μ l should be considered before delivery, especially if cesarean section is likely

AFLP, acute fatty liver disease of pregnancy; HELLP, hemolysis, elevated liver enzymes, low platelets; HG, hyperemesis gravidarum; IHCP, intrahepatic cholestasis of pregnancy.

Several liver injuries are unique to pregnancy and typically resolve with delivery. Accurate identification of the insult and the potential impact on both maternal and fetal health is imperative. The gestational age of the pregnancy is an important diagnostic clue and can help tailor the diagnostic evaluation, as these insults typically occur only at certain stages of development (see **Table 3**).

A thorough history, including prior pregnancies, high-risk behaviors and medications, and careful physical examination is essential (28).

First trimester

Hyperemesis gravidarum. HG is defined by persistent vomiting, associated with loss of 5% or more of pre-pregnancy body weight, dehydration, and ketosis. HG is uncommon (0.3–2% of pregnancies), occurs early in the first trimester, and typically resolves by 20 weeks gestation. Risk factors for HG include molar pregnancy, multiple pregnancies, trophoblastic disease, prior HG, and fetal abnormalities (triploidy, trisomy 21, and hydrops fetalis) (29). Liver test abnormalities are common in HG and resolve when the vomiting stops. In all, 50–60% of hospitalized women with HG will have a mild elevation in aminotransferase levels, although AST and ALT levels more than 20 times the upper limit of normal rarely have been reported (30). Jaundice and hepatic synthetic dysfunction are uncommon. Although women with HG have increased rates of low birth weight (LBW) babies, small for gestational age babies, preterm birth, and poor 5-min Apgar scores (31), outcomes are generally favorable (32,33). Management of HG is supportive, however, given the risk for electrolyte abnormalities and dehydration, hospitalization is not infrequent (34,35).

Second and third trimester

Intrahepatic cholestasis of pregnancy. IHCP is the most common liver disease in pregnancy with prevalence ranging between 0.3 and 5.6% (36–38). IHCP presents in the second and third trimesters as persistent pruritus, typically involving the palms and soles as well as the rest of the body, with elevated bile acid levels, and

resolves with delivery. Jaundice occurs in <25% of IHCP patients, always after the onset of pruritus. If jaundice is the presenting symptom, further evaluation for alternative explanations is necessary. Fat malabsorption can result in fat-soluble vitamin deficiencies requiring supplementation.

Risk factors for IHCP include advanced maternal age, a history of cholestasis secondary to oral contraceptives, and a personal or family history of IHCP. Some studies suggest a higher prevalence in patients with hepatitis C, cholelithiasis, and non-alcoholic fatty liver disease (37,39,40). Evaluation for alternative etiologies should be pursued if cholestasis fails to resolve after delivery.

In IHCP, bile acid concentrations are typically >10 μ mol/l with increased cholic acid levels and decreased chenodeoxycholic acid levels. Increased bile acid concentration (>40 μ mol/l) is one factor that can identify higher risk, and may be the only biochemical abnormality present. Bile acid levels also correlate with fetal distress. Most complications occur when bile acid levels exceed 40 μ mol/l (41). Aminotransferase levels may also be elevated, reaching values >1,000 U/l. Ultrasonography should be performed to exclude cholelithiasis.

Maternal outcomes are excellent, however, there is a risk of fetal distress, preterm labor, prematurity, and intrauterine death (41–45). Early delivery at 37 weeks is encouraged, because intrauterine death is more common in the last month of pregnancy and few deaths occur before 37 weeks (46).

First-line therapy for IHCP is UDCA at 10–15 mg/kg maternal body weight. It is well-tolerated and safe for both the mother and fetus. UDCA increases expression of bile salt export pumps and increases placental bile transporters. UDCA therapy normalized serum bile acid patterns in babies with minimal accumulation in amniotic fluid and cord blood (47). A recent meta-analysis also found that women who received UDCA had better outcomes with less pruritus, improved liver enzymes, and possibly improved fetal outcomes (48). UCDA is more effective than cholestyramine or dexamethasone in controlling pruritus. Dexamethasone may be used, if needed, to promote fetal lung maturity before delivery, as there is a higher rate of prematurity in IHCP.

Preeclampsia and eclampsia. Preeclampsia is characterized by new onset hypertension (systolic blood pressure ≥ 140 mm Hg or diastolic blood pressure ≥ 90 mm Hg) and proteinuria (≥ 300 mg/24 h) after 20 weeks of gestation (49,50). Organ dysfunction defines severe preeclampsia and can include hepatomegaly and hepatocellular injury. Up to 7.5% of all pregnancies are affected, but only 25% of preeclampsia cases are severe. Liver involvement is not a common expression and when it does occur symptoms are generally non-specific. Eclampsia is present when grand mal seizures occur (51).

Hepatic involvement can present with epigastric or right upper quadrant pain, likely from hepatomegaly stretching Glisson's capsule. Liver injury results as a consequence of vasoconstriction and fibrin precipitation in the liver. AST and ALT elevations can be striking. Complications can include hematoma below Glisson's capsule and hepatic rupture (52).

The magnitude of the liver chemistry abnormalities parallels the risk of adverse maternal but not fetal outcomes. Liver tests cannot exclusively be used to gauge clinical decisions, as the presence of normal liver enzymes does not exclude disease (53,54). An expectant approach is advised until after 34 weeks gestation to limit fetal morbidity (55). However, delivery is the only curative treatment and after 36–37 weeks there is no advantage in continuing the pregnancy (56).

HELLP syndrome. The HELLP syndrome is characterized by hemolytic anemia, increased liver enzymes, and low platelets. HELLP affects a minority of pregnancies but complicates up to 20% of cases of severe preeclampsia/eclampsia. Although HELLP typically presents between 28 and 36 weeks of gestation, 30% manifest symptoms in the first week postpartum (57). Risk factors include advanced maternal age, nulliparous, and multiparity (58).

The hypertension-related liver diseases share similar clinical presentations. Differentiation is difficult as there is overlap in their features. The diagnosis of HELLP is most often made through recognition of typical laboratory results. Signs of hemolytic anemia and thrombocytopenia with platelets $< 100,000$ cells/ μ l, elevations in AST, ALT, serum bilirubin, and lactate dehydrogenase are expected (57). There are no pathognomonic clinical signs and some women with HELLP may be asymptomatic. Right upper quadrant and epigastric pain, nausea, vomiting, malaise, headache, edema, and weight gain are common complaints. Hypertension and proteinuria should be expected, occurring in up to 80% of cases. Jaundice is rare, occurring in only 5% of patients.

Maternal consequences can be severe with mortality rates of 1–3% (59,60). Progression can also be rapid but laboratory values typically begin to normalize 48 h postpartum (60). Fetal prognosis is most strongly linked to gestational age at delivery and birth weight.

Hepatic consequences include hepatic infarction, subcapsular hematomas, and intraparenchymal hemorrhage. When the ALT or AST is $> 1,000$ U/l or abdominal pain radiates into the right shoulder, cross-sectional imaging can assist in excluding hepatic complications with more accuracy than ultrasound. Hepatic infarction should be suspected with right upper quadrant pain with fever,

whereas abdominal swelling or shock presentation can occur with hepatic rupture (61,62). Supportive management is appropriate for most contained hematomas. Surgery is indicated for those with enlarging hematomas or evidence of rupture with hemodynamic instability. Alternatively, successful percutaneous embolization of the hepatic arteries in stable women has been reported (63). Liver transplantation has also been an effective salvage in patients with continued decompensation despite standard interventions (64).

Glucocorticoids are often part of the therapeutic protocol in HELLP, especially in pregnancies < 34 weeks where they accelerate pulmonary maturity during expectant management. The University of Mississippi developed a treatment protocol that is often applied as standard of care in the management of women with HELLP. Known as "The Mississippi Protocol", it includes corticosteroids, magnesium sulfate, and systolic blood pressure control (65). However, a recent Cochrane review found that although dexamethasone resulted in a greater improvement in platelet count, there was no difference in the risk of maternal morbidity and mortality, or perinatal/infant death (66). Thrombocytopenia can be marked. There is no contraindication to platelet transfusion, and transfusion to $> 40,000$ cells/ μ l is advised when invasive procedures are anticipated (67).

Acute fatty liver disease of pregnancy. AFLP is a rare, life-threatening condition characterized by microvesicular fatty infiltration of the liver leading to hepatic failure. The median gestation age at the time of identification is 36 weeks. Risk factors include twin pregnancies and low body mass index (68).

Early recognition, prompt delivery, and supportive care are essential to optimize maternal and fetal prognosis, as the postpartum clinical course is dependent on the interval between symptoms and termination of the pregnancy (69). If hepatic function does not rapidly improve, evaluation for liver transplantation offers the patient the best chance for survival (69,70).

Presenting symptoms are non-specific: nausea, vomiting, and abdominal pain. Concomitant preeclampsia is present in roughly one half of the affected women (71). Striking aminotransferase elevations and hyperbilirubinemia are typical. Hepatic failure can manifest with signs of hepatic dysfunction such as encephalopathy, coagulopathy, and hypoglycemia. Renal dysfunction and pancreatitis are common (72).

The diagnosis of AFLP is usually made clinically based on compatible presentation, laboratory, and imaging results. The "Swansea Criteria" (Table 4) combine symptoms and laboratory derangements (73). These criteria have been validated in a large cohort in the United Kingdom, where the incidence of AFLP was 5.0 cases per 100,000 maternities. The "Swansea Criteria" had substantial agreement with the clinical diagnosis of AFLP. Although there was only 1 death in this series, 65% were admitted to an intensive care or specialty liver unit (69). When the Swansea Criteria were applied to a large group of women with suspected pregnancy-related liver disease who underwent liver biopsy, the screening tool offered an 85% positive predictive value and 100% negative predictive value for hepatic microvesicular steatosis. The authors felt confident that the Swansea Criteria could obviate the need for liver biopsy in clinical management (74).

Table 4. Swansea criteria for diagnosis of acute fatty liver of pregnancy

Six or more criteria required in the absence of another cause	
Vomiting	
Abdominal pain	
Polydipsia/polyuria	
Encephalopathy	
Elevated bilirubin	>14 μmol/l
Hypoglycaemia	<4 mmol/l
Elevated urea	>340 μmol/l
Leucocytosis	>11×10 ⁹ cells/l
Ascites or bright liver on ultrasound scan	
Elevated transaminases (AST or ALT)	>42 IU/l
Elevated ammonia	>47 μmol/l
Renal impairment; creatinine	>150 μmol/l
Coagulopathy; prothrombin time	>14 s or APPT>34 s
Microvesicular steatosis on liver biopsy	
ALT, alanine transaminase; APPT, activated partial thromboplastin time; AST, aspartate transaminase.	

The LCHAD enzyme catalyzes the step in beta-oxidation of mitochondrial fatty acid that forms 3-ketoacyl-CoA from 3-hydroxyacyl-CoA. There is a pathophysiologic pathway between fetal deficiency of LCHAD and AFLP. Homozygous-deficient offspring spill unmetabolized long-chain fatty acids into the maternal circulation. Accumulation of fetal or placental metabolites can lead to hepatotoxicity. Some women with AFLP are heterozygous for LCHAD and carry heterozygous or homozygous infants (75). In addition, not all genetic defects that lead to LCHAD confer a risk for AFLP (76).

Given the link between LCHAD deficiency and AFLP, the offspring of women with AFLP should be monitored closely for manifestations of LCHAD deficiency as most symptoms are reversible with adequate energy supply (74,77). No clear genotype-phenotype correlation exists, however, heart, liver, and skeletal muscle are frequently involved. Case reports confirm heterogeneous clinical phenotypes including hypoketotic hypoglycemia, fatty liver, infantile cholestasis, and hypocalcemia (74,77,78).

COINCIDENT LIVER DISEASE (HAV, HEV, HSV)

Recommendations:

20. Pregnant women presenting with acute hepatitis should be tested for common etiologies of acute liver injury including viral hepatitis, hepatitis A virus (HAV), hepatitis B virus (HBV), hepatitis E virus (HEV), and herpes simplex virus (HSV; strong recommendation, very low level of evidence).
21. Pregnant women with acute hepatitis suspected from HSV should be initiated on acyclovir (strong recommendation, very low level of evidence).

There are no published systematic reviews or meta-analysis on the evaluation and management of hepatitis A, hepatitis E, or HSV hepatitis during pregnancy.

Although acute infection with HAV has been associated with preterm labor and premature rupture of membranes, this has been reported to have no significant impact on maternal or fetal outcomes (79). The pregnant state does not appear to alter the course of acute HAV infection. Nevertheless, pregnant women presenting with acute hepatitis should be tested for HAV-IgM as vertical transmission of HAV has been reported, even leading to outbreaks within neonatal care units (80,81). In addition to careful infection control precautions, the CDC recommends HAV immunoglobulin treatment for the neonate if the maternal HAV infection occurs within 2 weeks of delivery (82). Treatment is otherwise supportive.

HEV infection has achieved notoriety with its association with pregnancy and reports of increased risk of acute liver failure leading to high maternal and infant mortality in Southeast Asia (83,84). Reports of acute HEV are rare in the United States and Europe although it may be under-diagnosed owing to limited awareness regarding HEV (85,86). However, pregnant women presenting with acute hepatitis should be tested for HEV with HEV-IgM to make the diagnosis and to increase anticipation and preparation for possible progression to acute liver failure and need for liver transplantation evaluation. Treatment is otherwise supportive.

Although hepatitis from HSV is very rare, HSV seroprevalence is common in women of child-bearing age in the United States at ~20% for HSV-2 and 60% for HSV-1 (87). Clinical clues to HSV hepatitis are the presence of fever, upper respiratory infection symptoms, or an anicteric, severe hepatitis presentation on laboratory testing. The pathognomonic mucocutaneous lesions are present in <50% of cases, requiring a high index of suspicion for HSV in the pregnant patient with an acute hepatitis presentation. The challenge of HSV hepatitis is that the diagnosis is difficult to make and has extremely high mortality rates reported up to 74% (88). This diagnostic difficulty is compounded by limited specificity and sensitivity of routine HSV-IgM testing. HSV PCR should be performed when HSV hepatitis is suspected (89,90).

Empiric acyclovir is recommended if HSV hepatitis is suspected in a pregnant patient. Acyclovir is already recommended by the American College of Obstetrics and Gynecology as prophylaxis at 36 weeks of pregnancy to prevent HSV recurrence and vertical transmission in women with previous infection with HSV (91). Acyclovir should be started once HSV hepatitis is suspected, as the diagnosis is difficult to make and often delayed and as acyclovir has been shown to be safe and well-tolerated in pregnancy (92–94). As HSV hepatitis is associated with poor outcomes, even with appropriate acyclovir treatment initiation and availability of liver transplantation, there is little to lose in initiating acyclovir once HSV hepatitis is suspected as early treatment is associated with improvement in outcomes (89,95). On the other hand, empiric acyclovir is not recommended in all pregnant patients with hepatitis when

HSV infection is not suspected (96). The key is to have a low threshold to suspect HSV hepatitis, especially if the pregnant patient has a fever, anicteric severe hepatitis on laboratory testing, and a rash. Acyclovir can then be discontinued if the HSV PCR is negative.

Acute HBV infection or reactivation of HBV can present during pregnancy and it may be difficult to differentiate reactivation from acute HBV infection. Nevertheless, HBV testing with HBsAg and hepatitis B core IgM is recommended in pregnant patients presenting with acute hepatitis. Management of HBV during pregnancy is covered elsewhere in this guideline.

CHRONIC LIVER DISEASES, CIRRHOSIS, AND LIVER TRANSPLANTATION

Recommendations:

Hepatitis B.

22. Active-passive immunoprophylaxis with hepatitis B immune globulin and the HBV vaccination series should be administered to all infants born to HBV-infected mothers to prevent perinatal transmission (strong recommendation, low level of evidence).
23. Women chronically infected with HBV and high viral load ($>200,000$ U/ml or $>10^6$ log copies/ml and higher) should be offered antiviral medication with tenofovir or telbivudine in the third trimester to reduce perinatal transmission of HBV (strong recommendation, low level of evidence).
24. C-section should not be performed electively in HBV-positive mothers to prevent fetal infection (strong recommendation, very low level of evidence).
25. Women chronically infected with HBV should be allowed to breastfeed as recommended for infant health (strong recommendation, very low level of evidence).

Chronic HBV infection is estimated to affect >350 million people worldwide and represents a significant source of morbidity and mortality related to cirrhosis and hepatocellular carcinoma. Mother-to-child transmission (MTCT) of HBV remains an important source of incident cases of HBV. Current barriers to eradication of incident HBV infections via MTCT include underutilization of immunoprophylaxis with hepatitis B vaccination and hepatitis B immunoglobulin in certain endemic regions as well as failure of immunoprophylaxis.

The risk for development of chronic HBV infection is strongly linked to the age of exposure. Risk for chronic infection after exposure varies from $\sim 90\%$ in infants, 50% in toddlers and young children, and 5% in adults (97). MTCT rates also vary significantly according to the mother's HBeAg status ($70\text{--}90\%$ transmission rate for HBeAg+ mothers vs. $10\text{--}40\%$ for HBeAg-mothers). Standard active-passive immunoprophylaxis with HBIG and hepatitis B vaccination administered immediately after birth (within 12 h) to infants of HBsAg-positive mothers, followed by 2 additional doses of vaccine within 6–12 months, prevents transmission in $\sim 95\%$. However, recent review of published literature from 1975 to 2011 demonstrated

that active-passive immunoprophylaxis fails to prevent HBV transmission in 8–30% of children born to highly viremic mothers (98). Postulated causes of immunoprophylaxis failure include high levels of maternal viremia, intrauterine infection, or mutations of the HBV surface protein (99,100). Thus a clinical need remains to identify all causes of immunoprophylaxis failure and to determine safe and effective means of reducing MTCT rates.

High maternal viremia is correlated with the highest risk for the transmission of HBV in pregnancy. In a large, nested case-control study of 773 HBsAg-positive women in Taiwan, high levels of HBV DNA (≥ 1.4 ng/ml or $\sim 3.8 \times 10^8$ copies/ml) in HBeAg-positive women was associated with an odds ratio of 147 for chronic infection in infants (101). Even in the era of immunoprophylaxis, viremia remains a strong predictor of MTCT. In a study of 138 babies born to HBsAg-positive women, Wiseman et al. (102) found the immunoprophylaxis failure rate to be 9%, all occurring with mothers who were HBeAg-positive with HBV DNA $\geq 8 \log_{10}$ copies/ml (2×10^7 U/ml). Recent literature also provides useful data to risk stratify the magnitude of MTCT risk and immunoprophylaxis failure according to varying thresholds of maternal HBV DNA. These data suggest that HBV DNA levels of $6\text{--}6.99 \log_{10}$ copies/ml (2×10^5 IU/ml to 1.9×10^6 IU/ml) portends a 3% risk of transmission, $7\text{--}7.99 \log_{10}$ copies/ml (2×10^6 IU/ml to 1.9×10^7 IU/ml) a 7% risk of transmission, and $>8 \log_{10}$ copies/ml (2×10^7 IU/ml) in the mother portend an 8% risk of MTCT of HBV (103).

Older data assessing MTCT rate in infants born via cesarean section vs. vaginal delivery failed to conclusively show a significant difference in neonatal HBV infection. Expert opinion has suggested that there were insufficient data to recommend changes in the mode of delivery for HBV-infected women (104,105). Some more recent data support reconsideration of elective cesarean section to reduce MTCT including a meta-analysis that suggested a 17.5% absolute risk reduction compared with immunoprophylaxis alone. However, other studies report no benefit to elective cesarean section (106). Data from Beijing of 1,409 infants born to HBsAg-positive mothers from 2007 to 2011, all of whom received appropriate immunoprophylaxis at birth, reported MTCT rates of 1.4% with elective cesarean section compared with 3.4% with vaginal delivery and 4.2% with urgent cesarean section ($P < 0.05$) (107). When mothers in this study were stratified according to HBV DNA, in those with low HBV DNA ($< 1,000,000$ copies/ml or 2×10^5 IU/ml), delivery modality did not impact MTCT. This suggests a potential role for elective cesarean section among women with HBV DNA $> 1,000,000$ copies/ml (2×10^5 IU/ml). However, before definitive recommendations can be made, validation studies are needed to determine the relative safety and efficacy of elective cesarean section and immunoprophylaxis vs. immunoprophylaxis alone in reducing MTCT without compromising fetal outcomes (107,108).

There is a growing body of literature to support both the safety and efficacy of antiviral therapy initiated in late pregnancy for reduction of MTCT among women in the highest risk

for immunoprophylaxis failure (those with HBV DNA levels in the range of 10^7 log copies/ml and higher). Han conducted a prospective, open-label trial of women aged 20–40 years who were HBeAg+ with HBV DNA $>7 \log_{10}$ copies/ml (2×10^6 IU/ml) between gestation week 20–32. All women were offered antiviral therapy and 135 who accepted received telbivudine 600 mg daily. The comparison arm consisted of 94 women who consented to participate in the trial but declined antiviral therapy. All infants were administered appropriate immunoprophylaxis. Mean viral load at enrollment was $\sim 8 \log_{10}$ copies/ml (2×10^7 IU/ml) in both arms and was reduced to $2.44 \log_{10}$ copies/ml in the telbivudine-treated arm before delivery. The reported MTCT rate was 0% with telbivudine therapy compared with 8% without antiviral therapy. One infant in each group had LBW and there were 6 infants in the telbivudine group compared with 5 infants in the control group with pneumonia by age 7 months. No congenital abnormalities were identified (103). In a similar study, Pan *et al.* (109) compared 53 women with HBeAg+ HBV with viral loads $>6 \log_{10}$ copies/ml and elevated ALT treated with telbivudine initiated in the second or third trimester with 35 similar women who declined therapy. Immunoprophylaxis failure rate in this study was 0% with telbivudine therapy compared with 8.6% in controls with no significant difference in adverse event rates out to 28 weeks postpartum.

In one multicenter, prospective study from Australia, 58 women with HBV DNA $>7 \log_{10}$ IU/ml (2×10^6 IU/ml) commencing therapy with tenofovir dipivoxil at 32 weeks gestation were compared with women ($n=52$) treated with lamivudine and untreated historical controls ($n=20$). Perinatal transmission was reduced to 0 and 2% in the lamivudine and tenofovir cohorts, respectively, compared with 20% in the untreated groups. No differences were noted in obstetric or infant safety outcomes (110). Although some studies have suggested a favorable safety profile for antiviral therapy even in the first and second trimesters of pregnancy, when utilized purely for purposes of reducing MTCT, antiviral therapy should be initiated in the third trimester (thus minimizing the risk associated with fetal exposure to these medications). Treatment at levels lower than 10^6 log copies/ml (2×10^5 IU/ml) does not appear to be indicated unless the pregnant woman has liver disease for which viral suppression is indicated. The end point of antiviral therapy administered to reduce risk of MTCT typically is immediately in the postpartum period for mothers who plan to breastfeed their infants, unless treatment continuation is indicated for the clinical benefit of the mother. Discontinuation of therapy at any point during or after pregnancy requires careful monitoring because of the potential for HBV flares upon antiviral therapy withdrawal.

Transmission of HBV with breastfeeding is low risk in infants who receive appropriate immunoprophylaxis. Current WHO recommendations are to allow breastfeeding as there is no evidence for additional risk, even without immunization. (Protection against viral hepatitis, Recommendations of Immunization Practices Advisory Committee (ACIP), MMWR 1990;39(no S-2) WHO Update No 22, Nov 1996) Breastfeeding should be

avoided in the presence of breast pathology such as cracked or bleeding nipples. Oral nucleos(t)ide analogs have been shown to be excreted in breast milk, albeit at low levels, and there is limited data on the effect of these medications on infants (111).

Hepatitis C (HCV)

26. All pregnant women with risk factors for HCV should be screened with anti-HCV antibody. Screening should not be performed in women without risk factors for HCV acquisition (strong recommendation, low level of evidence).
27. Invasive procedures (e.g., amniocentesis, invasive fetal monitoring) should be minimized in infected mothers and their fetus to prevent vertical transmission of hepatitis C (strong recommendation, very low level of evidence).
28. C-section should not be performed electively in HCV-positive mothers to prevent fetal infection (strong recommendation, very low level of evidence).
29. Women chronically infected with HCV should be allowed to breastfeed as indicated for infant health (strong recommendation, very low level of evidence).
30. Hepatitis C therapy should not be offered to pregnant women to either treat HCV or decrease the risk for vertical transmission (strong recommendation, very low level of evidence).

Chronic infection with the HCV can lead to significant liver-related morbidity and increases in all-cause mortality. Conservatively, >3 million Americans are estimated to be chronically infected with HCV, with 75% born between 1945–1965. Prevalence is generally low in the prenatal population (112).

HCV has little impact during pregnancy with minimal risk to either the mother or infant. However, there may be a higher risk for premature rupture of membranes and gestational diabetes in women with HCV (113,114). ALT and viral loads fluctuate but these changes lack clinical significance. Pregnancy induces a state of relative immune suppression followed by immune reconstitution postpartum. The changes in liver enzymes and viral kinetics mirror a response to this immune modulation. During the second and third trimester aminotransferase levels decline, only to rebound postpartum. Viral load also fluctuates, peaking during the third trimester then returning to pre-pregnancy levels after delivery (115,116). Unlike HBV, postpartum flares of HCV have not been described.

Although HCV is transmitted through percutaneous exposure of infected blood or body fluids, screening for HCV is not part of routine perinatal testing owing to a combination of low rates of perinatal transmission and low prevalence of HCV in pregnant women. Cross-sectional studies estimate that only 0.5–8% of pregnant women have anti-HCV (117,118). As in the general population, the prevalence of anti-HCV is higher in those who engage in risk factors that increase potential exposure. Pregnant women should be screened using the same guidelines as the general population (119,120).

Although there is only a 3–10% risk of transmitting HCV at the time of birth, vertical transmission remains responsible for the majority of childhood HCV infection. This risk is highest in pregnant women co-infected with HIV. Unfortunately, there is no perinatal management strategy that can clearly decrease this risk. Although studies have reported conflicting findings, it is generally recommended that invasive procedures, such as internal fetal monitoring devices, should be avoided (121).

Although prolonged (>6h) rupture of membranes may increase the risk of transmission, vaginal delivery itself does not appear to increase the risk of vertical transmission of HCV transmission compared with cesarean delivery (121,122).

There is no evidence of an association between breastfeeding and risk for vertical transmission (121). Still, breastfeeding should be avoided when the potential risk for exposure is higher, such as when there are cracked nipples or skin breakdown.

HCV can be eradicated effectively with either all-oral- or interferon-based treatment options. HCV rarely requires urgent therapy, making it easier to defer treatment decisions until after delivery. In addition, both interferon and ribavirin are strictly contraindicated during pregnancy. There is no data at this time to guide or support the use of all-oral combination therapy during pregnancy.

Autoimmune hepatitis

31. Pregnant women with autoimmune hepatitis (AIH) should be continued on their treatment with corticosteroids and/or azathioprine (AZA) (strong recommendation, very low level of evidence).
32. Pregnant women with primary biliary cirrhosis (PBC) should be continued on their treatment with UDCA (strong recommendation, very low level of evidence).
33. Pregnant women with Wilson's disease (WD) should be continued, with dose reduction if possible, on their treatment with penicillamine, trientine, or zinc (strong recommendation, very low level of evidence).
34. Pregnant women with suspected portal hypertension should undergo screening with upper endoscopy for esophageal varices in the second trimester (strong recommendation, low level of evidence).
35. Pregnant women who are found to have large esophageal varices should be treated with beta-blockers and/or band ligation (conditional recommendation, very low level of evidence).
36. Pregnant women with a history of liver transplantation should continue their immunosuppression except for mycophenolic acid (strong recommendation, moderate level of evidence).

There are no published systematic reviews or meta-analysis on the management of AIH, PBC, or WD during pregnancy although there are several systematic reviews on treatment for these diseases in general.

The key for successful pregnancy outcomes in women with chronic liver disease appears to be appropriate counseling regarding fertility and optimal management of the liver disease before, during, and after the pregnancy. The most challenging issue in this setting is the management of medications used for the treatment of the underlying chronic liver disease with regard to dosing, effectiveness, and safety. Limiting the discussion is the paucity of data on specific medications in the setting of liver disease and pregnancy. Nevertheless, a principle that becomes evident in reviewing the intersection of medical therapy, chronic liver disease, and pregnancy is that a healthy mother has the best chance to have a healthy baby and optimal maternal outcomes. Thus, in women with chronic liver diseases, such as AIH, PBC, or WD, contemplating pregnancy, optimal control of the chronic liver disease is advised. The risks of not treating the liver disease in the pregnant state with subsequent risk to maternal and fetal health outcomes must be considered in addition to the benefits and risks of the treatment regimens.

It is difficult to discriminate between the potential impact of underlying maternal liver diseases and therapies for these diseases, on the risks of maternal or fetal complications.

Moreover, because adverse events such as congenital malformations are very rare, available data are limited to case reports and case series. The limited data on the effectiveness and safety of therapies for these liver diseases during pregnancy has often led to dependence on extrapolated data from use of these therapies during pregnancy in other disease processes in pregnancy such as inflammatory bowel disease, autoimmune diseases, or organ transplantation. The limitations of such extrapolations must be acknowledged, and caution taken in generalizing these conclusions to patients with liver disease.

AIH is associated with an increased risk of fetal prematurity and loss, with worse outcomes with inadequate AIH activity control, especially in the absence of or discontinuation of AIH treatment before or during pregnancy (123). Although AIH was historically thought to be quiescent during pregnancy, more recent data suggest that AIH may have an initial presentation during pregnancy, an intrapartum flare risk of >20% and postpartum flare risk of up to 30–50% (124,125). Treatment for AIH is based on immunosuppression with corticosteroids and/or AZA, with recent practice guidelines for AIH recommending prednisone monotherapy for pregnant individuals (126). A systematic review of AIH treatment concluded that corticosteroids ±AZA was appropriate for induction whereas corticosteroids +AZA or AZA monotherapy was superior to corticosteroid monotherapy for maintenance management of AIH (127). However, there are no systematic reviews or meta-analysis on the treatment of AIH during pregnancy. In the absence of such data, it is important to consider that flares of AIH during pregnancy may be potentially more detrimental to neonatal outcomes than the potential risk of medical therapy needed to control and prevent AIH flares.

Corticosteroids, pregnancy category C drugs, have been studied in a population-based study of >51,000 corticosteroid-exposed

pregnancies, with no increase in orofacial cleft defects or other significant adverse events (127). Corticosteroid monotherapy has traditionally been used for the management of AIH flares during pregnancy because AZA is a pregnancy category D drug, which has limited its use (127). Concerns regarding AZA arose from animal studies using suprapharmacologic doses and non-oral delivery routes such as intraperitoneal or subcutaneous dosing, associated with limbic malformations, cleft palate, skeletal anomalies, and hematopoietic suppression. However, utilization of AZA during pregnancy for treatment of AIH has been reported to be safe in a limited number of case reports and series (128–136). AZA treatment in AIH during pregnancy has not been studied systematically. However, utilization of AZA during pregnancy has been studied systematically in inflammatory bowel disease with 3,000 AZA-exposed pregnancies showing an association with preterm births but no increase in congenital abnormalities or LBWs (137). Studies of AZA in other autoimmune diseases and inflammatory bowel disease have found scattered reports of preterm births but no increased risk of congenital abnormalities, spontaneous abortions, or infections supporting the growing evidence regarding the acceptability of AZA during pregnancy (138–142). The mounting evidence of AZA's safety during pregnancy coupled with the importance of achieving and maintaining AIH disease control during pregnancy supports the mandate that treatment continuation for AIH is critical in optimizing maternal and fetal outcomes. The potential benefit of treatment with corticosteroids and AZA to keep the mother's AIH in control appears to be significantly greater than the potentially small risk of treatment-associated adverse events on the mother and fetus.

Primary biliary cirrhosis. Older literature suggested poor outcomes of pregnancy in patients with PBC (143). As patients with PBC tend to present at an older age after the usual child-bearing age, and as women with PBC were discouraged in the past from pursuing pregnancy, there is an extremely limited number of studies on PBC and pregnancy. However, more recent studies have reported good maternal and fetal outcomes (144). PBC has been associated with disease flare after delivery (144,145). UDCA is a pregnancy category B drug that is generally recommended for PBC (146). Studies on the use of UDCA treatment for PBC during pregnancy have been limited, especially in the first trimester (147,148). Similar to the situation with AIH, the potential risks of UDCA during pregnancy appear small compared with the potential positive effect of treatment on maternal and fetal outcomes. With growing evidence that UDCA is safe during pregnancy in other diseases such as intrahepatic cholestasis of pregnancy, and the unlikely scenario that large-scale studies will be performed on the efficacy and safety of UDCA during pregnancy for PBC, it appears prudent to recommend continuation of UDCA for PBC during pregnancy at this time (149,150).

Wilson's disease. WD is postulated to lead to reduced fertility as copper deposition in the uterus may interfere with embryo

implantation leading to an increase in miscarriages and spontaneous abortions (151). WD and the complex nature of its management would benefit from referral to high-risk pregnancy multidisciplinary specialists in maternal–fetal medicine and liver disease. Pregnancy in general does not appear to change the course of WD progression (152). However, treatment discontinuation or a lack of treatment has been reported to lead to disease flares with attendant risk of hepatic decompensation or liver failure (153). There is one recent systematic review on the treatment of WD in general, but no reports specific to treatment for WD during pregnancy (154). Similar to AIH and PBC, the decision regarding treatment for WD must weigh the potential risks and adverse effects of treatment vs. not only the benefits of treatment but the risks of not treating the WD during pregnancy. Practice guidelines for WD recommends continuing treatment during pregnancy, but reducing penicillamine or trientine doses by 25–50% to promote wound healing in the event that a cesarean section is needed (155). There is inadequate data to make recommendations on a preferred treatment for WD during pregnancy, between penicillamine, trientine, or zinc. Some data on conversion to zinc therapy during pregnancy has also been reported (156–158). There are also multiple case reports of fetal myelosuppression or embryopathy associated with penicillamine treatment during pregnancy for WD (159–162). On the other hand, treatment discontinuation or lack of treatment for WD can not only lead to maternal hepatic decompensation but can also lead to copper deposition in the placenta and fetal liver, damaging the fetus along with recognized risks of maternal hepatic decompensation. The risks of treatment discontinuation or lack of treatment for WD during pregnancy appears to outweigh the potential risks of treatment. The data to recommend dose reduction of penicillamine in anticipation of possible cesarean section appears to be very limited.

Cirrhosis and portal hypertension. There are no published systematic reviews or meta-analyses on the management of cirrhosis or portal hypertension during pregnancy, likely because of the low prevalence of cirrhosis in women of reproductive age and reduced fertility of women with cirrhosis. Appropriate discussion regarding pregnancy and counseling regarding the management of cirrhosis during pregnancy is critical for optimizing outcomes. Pregnant women with cirrhosis should ideally be managed in a multidisciplinary setting with maternal–fetal medicine along with gastroenterology/hepatology (163). Similar to the management of chronic liver disease in pregnancy, the principle of optimizing the management of cirrhosis and portal hypertension appears prudent to enhance maternal and fetal outcomes.

Pregnancy in women with underlying cirrhosis has been associated with an increase in prematurity, spontaneous abortions, and maternal–fetal mortality (164–166). Non-cirrhotic portal hypertension has been reported to have better outcomes than cirrhotics with portal hypertension (167). Variceal bleeding is the most frequent and feared complication of portal hypertension during pregnancy, with an increased risk at delivery and

the second trimester, potentiated by an increase in intravascular volume, compression from the gravid uterus, and repeated Valsalva maneuvers (166). Up to 30% of cirrhotic pregnant women bleed from esophageal varices during pregnancy, and the risk of variceal bleeding increases up to 50–78% if there are pre-existing varices (163,167,168). Each episode of variceal bleeding leads to maternal mortality rates as high as 20–50%, with an even higher risk of fetal loss (169). Variceal bleeding during pregnancy is managed very similarly to variceal bleeding in general given the acute and life-threatening nature of the event, with a focus on endoscopic hemostasis and supportive care for the mother and fetus (170). Octreotide is a pregnancy category B drug and appears to be safe as an adjunct treatment in acute variceal bleeding along with antibiotics. Salvage therapy with transjugular intrahepatic systemic shunts and liver transplantation has also been described, but are not routinely advocated (171,172).

As outlined in the general endoscopy section above, endoscopy during pregnancy appears safe, but must be considered carefully in terms of the indication for endoscopy, the risks vs. benefit evaluation and whether it will lead to management changes (15,173).

Given the risks of variceal bleeding in cirrhotic women during pregnancy, the significantly increased mortality associated with such bleeding, and the opportunity to intervene if varices are identified preemptively, the indications for screening for esophageal varices appears to have at least a moderate indication. Considered against the small, but not insignificant risk of sedation and endoscopy, the benefits appear to outweigh the risks. Timing of screening for esophageal varices appears most prudent in the second trimester, after organogenesis is complete in the first trimester and before the greatest risk of bleeding at delivery.

Despite acceptance of band ligation and beta-blockers as first-line management of esophageal varices for non-pregnant patients, there are limited data on their efficacy and safety in pregnancy (174–176). Propranolol is a pregnancy category C drug, but has been used to treat fetal arrhythmias as well as maternal conditions such as thyrotoxicosis, arrhythmias, or hypertension. There are risks of intrauterine growth retardation, neonatal bradycardia, and hypoglycemia, but propranolol appears overall to be safe in pregnant patients. Nadolol is also a category C drug, but has a long half-life owing to low protein-binding and low rate of excretion, so is not preferred (177).

Traditionally, vaginal delivery with a short second stage of labor has been advocated along with consideration of forceps or vacuum extraction, if needed (178). However, the recognition that prolonged vaginal delivery may be associated with an increased risk of variceal bleeding owing to repeated Valsalva maneuvers has led to an interest in considering cesarean sections as an alternative. Cesarean sections may be required for fetal distress or prematurity, but carries an increased risk of bleeding complications from the surgical site in the setting of portal hypertension. Regardless, there is no data comparing the benefits of vaginal delivery vs. cesarean section. If performed, it would be judicious to arrange for vascular surgery support in case of difficult to control collateral bleeding at the surgical site.

Liver transplantation. Fertility is rapidly restored after successful liver transplantation, with reports of 80% normalization of the menstrual cycle within 1 year and as early as a few months after liver transplantation (179). Most experts advocate waiting at least 1 year, and some up to 2 years after liver transplantation before planning a pregnancy, citing the lower doses of immunosuppression use, lower risk of acute cellular rejection, and lower risk of opportunistic infections after the first year of liver transplantation (180). The key is to initiate timely and appropriate discussions with the patient regarding fertility and pregnancy possibilities, with the goal of planned management with maternal–fetal medicine providers and the liver transplant center.

There is one published systematic review on pregnancy outcomes in liver transplant recipients (181). Higher rates of preterm births and cesarean sections compared with the general population were reported. The National Transplantation Pregnancy Registry, a questionnaire-based registry, has reported a higher risk of prematurity, LBW, maternal hypertension and preeclampsia, and cesarean sections compared with the general population (182). Higher risk of acute cellular rejection and graft loss were noted if pregnancy occurred within 6 months of liver transplantation. Overall, the literature suggests that pregnancy in liver transplant recipients is safe and not uncommon, with good outcomes given careful management and monitoring (183,184). The key is to maintain liver graft function to support the mother's health to maximize the opportunity for a healthy pregnancy and delivery of a healthy baby (185).

There is one meta-analysis on pregnancy and cyclosporine in transplant recipients (186). There are no other meta-analyses or systematic reviews on pregnancy and use of tacrolimus, AZA, mycophenolic acid, sirolimus, everolimus, or corticosteroids in the setting of liver transplantation. It should be noted that reports of maternal and fetal outcomes, and potential adverse events while on these immunosuppressive medications may be confounded by the underlying disease activity, concomitant medical comorbidities, other medications being utilized, as well as the pregnancy state itself in the post-liver transplant setting. Overall, with the exception of mycophenolic acid, the risks of cyclosporine, tacrolimus, AZA, sirolimus, everolimus, and corticosteroids appear low compared with the risks of acute cellular rejection or graft loss with their discontinuation or attenuation. Although a higher risk of prematurity and LBW have been reported, the risks of congenital malformation do not appear to be significantly higher than the risk in the general population, without a specific pattern of malformation identified (187–192). Compared with tacrolimus and cyclosporine, there is less data on the use of everolimus and sirolimus during pregnancy after liver transplantation, with more of the data available for kidney transplant recipients. The potential for impaired wound healing with everolimus and sirolimus must be considered if cesarean section is performed (193–196). It is clear that mycophenolic acid should not be used during pregnancy owing to risk of congenital malformations and embryo-fetal toxicity (197–200).

Expert and society recommendations have traditionally opposed breastfeeding in the setting of immunosuppression medications and transplantation, given the potential for harm of these medications and a lack of safety data (201). More recently, small series have reported safety with minimal to no adverse events for babies

who are breastfed while mothers are on immunosuppression medications after liver transplantation (202–205). In addition, pharmacokinetic and drug safety data on breast milk concentrations have suggested minimal excretion of these immunosuppressants into breast milk (206–208). The accumulation of these data, albeit still limited, in addition to the growing recognition of the importance of breastfeeding, has led to a push to loosen these traditional dictums against breastfeeding, especially if the mother is interested in breastfeeding her baby.

CONCLUSION

Clinical evaluation of the pregnant woman who presents with liver test abnormalities relies on the accurate determination of intrinsic liver disease or liver disease related specific to pregnancy. Judicious and timely evidence-based management most often results in good maternal and fetal outcomes.

ACKNOWLEDGMENTS

We thank Michael Chang, Janice Jou, Barry Schlansky (Oregon Health and Science University), and Vinay Sundaram (Cedars Sinai) for their helpful comments on the manuscript.

CONFLICT OF INTEREST

Guarantor of the article: Tram T. Tran, MD, FACG, FAASLD.

Specific author contributions: All the authors contributed to planning and writing of manuscript, and collecting and/or interpreting data. All authors approved the final draft submitted.

Financial support: None.

Potential competing interests: Tram T. Tran has received research grants from Gilead Sciences and BMS; and has been a consultant/advisory board member/speaker for Gilead Sciences and BMS. Nancy S. Reau has been a member of the research/advisory board for: Abbvie, Gilead, BMS, and Janssen; and an advisory board member for Merck. Joseph Ahn declares no competing interests.

REFERENCES

- Eddy DM. A manual for assessing health practices and designing practice guidelines. 1996, American College of Physicians: Philadelphia, PA, USA 1–126.
- Guyatt GH, Oxman AD, Vist GE *et al*. GRADE: an emerging consensus on rating quality of evidence and strength of recommendations. *BMJ* 2008;336:924–6.
- Robson SC, Mutch E, Boys RJ *et al*. Apparent liver blood flow during pregnancy: a serial study using indocyanine green clearance. *Br J Obstet Gynaecol* 1990;97:720–3.
- Torloni MR, Vedmedovska N, Merialdi M *et al*. ISUOG-WHO Fetal Growth Study Group. Safety of ultrasonography in pregnancy: WHO systematic review of the literature and meta-analysis. *Ultrasound Obstet Gynecol* 2009;33:599–608.
- Guidelines for diagnostic imaging during pregnancy. ACOG Committee Opinion No. 299. American College of Obstetricians and Gynecologists. *Obstet Gynecol* 2004;104:647–51.
- Cunningham FG, Gant NF, Leveno KJ *et al*. General considerations and maternal evaluation. In *Williams Obstetrics*, 21st ed. McGraw-Hill: New York, NY, USA, 2001, 1143–58.
- Patenaude Y, Pugash D, Lim K *et al*. The use of magnetic resonance imaging in the obstetric patient. *J Obstet Gyn Can* 2014;36:349–63.
- Mehta PS, Metha SJ, Vorherr H. Congenital iodide goiter and hypothyroidism: a review. *Obstet Gynecol Surv* 1983;38:237–47.
- Mammen T, Keshava SN, Eapen CE *et al*. Transjugular liver biopsy: a retrospective analysis of 601 cases. *J Vasc Interv Radiol* 2008;19:351–8.
- Keshava SN, Mammen T, Surendrababu NRS *et al*. Transjugular liver biopsy: what to do and what not to do. *Indian J Radiol Imaging* 2008;18:245–8.
- Gilinsky NH, Muthunayagam N. Gastrointestinal endoscopy in pregnant and lactating women: emerging standard of care to guide decision-making. *Obstet and Gynecol Survey* 2006;61:791–9.
- Glosten B. *Anesthesia for Obstetrics* Miller RD (ed). Anesthesia Churchill Livingstone: New York, NY, USA, 2000, 2025–68.
- Qadeer MA, Vargo JJ, Khandwala F *et al*. Propofol versus traditional sedative agents for gastrointestinal endoscopy: a meta-analysis. *Clin Gastroenterol Hepatol* 2005;3:1049–56.
- Jiraki K. Lethal effects of normeperidine. *Am J Forensic Med Pathol* 1992;13:42–3.
- Cappell MS. Risks versus benefits of gastrointestinal endoscopy during pregnancy. *Nat Rev Gastroenterol Hepatol* 2011;8:610–34.
- Tham TCK, Vandervoort J, Wong RCK *et al*. Safety of ERCP during pregnancy. *Am J Gastroenterol* 2003;98:308–11.
- Axelrad AM, Fleischer DE, Strack LL *et al*. Performance of ERCP for symptomatic choledocholithiasis during pregnancy: techniques to increase safety and improve patient management. *Am J Gastroenterol* 1994;89:109–12.
- Jamidar PA, Beck GJ, Hoffman BJ *et al*. Endoscopic retrograde cholangiopancreatography in pregnancy. *Am J Gastroenterol* 1995;90:1263–76.
- Kahaleh M, Hartwell GD, Arseneau KO *et al*. Safety and efficacy of ERCP in pregnancy. *Gastrointest Endosc* 2004;60:287–92.
- Tang SJ, Mayo MJ, Rodriguez-Frias E *et al*. Safety and utility of ERCP during pregnancy. *Gastrointest Endosc* 2009;69:453–61.
- Steinbrook RA, Brooks DC, Datta S. Laparoscopic cholecystectomy during pregnancy. Review of anesthetic management, surgical considerations. *Surg Endosc* 1996;10:511–5.
- Date RS, Kaushal M, Ramesh A. A review of the management of gallstone disease and its complications in pregnancy. *Am J Surg* 2008;196:599–608.
- Kuy S, Roman SA, Desai R *et al*. Outcomes following cholecystectomy in pregnant and nonpregnant women. *Surgery* 2009;146:358–66.
- Marerro J, Ahn J, Reddy KR. ACG Clinical guideline: the diagnosis and management of focal liver lesions. *Am J Gastroenterol* 2014;109:1327–47.
- Stoot JH, Van Roosmalen J, Terpstra OT. Life-threatening hemorrhage from adenomas in the liver during pregnancy. *Dig Surg* 2006;23:155.
- van Aalten SM, de Man RA, IJzermans JN *et al*. Systematic review of haemorrhage and rupture of hepatocellular adenomas. *Br J Surg* 2012;99:911–6.
- Rifai K, Mix H, Potthoff A *et al*. No evidence of substantial growth progression of complications of large focal nodular hyperplasia during pregnancy. *Scand J Gastroenterol* 2013;48:88–92.
- Hay JE. Liver disease in pregnancy. *Hepatology* 2008;47:1067–76.
- Einarson TR, Piwko C, Koren G. Quantifying the global rates of nausea and vomiting of pregnancy: a meta analysis. *J Popul Ther Clin Pharmacol* 2013;20:e171–83.
- Conchillo JM, Pijnenborg JM, Peeters P *et al*. Liver enzyme elevation induced by hyperemesis gravidarum: aetiology, diagnosis and treatment. *Neth J Med* 2002;60:374–8.
- Veenendaal MV, van Abeelen AF, Painter RC *et al*. Consequences of hyperemesis gravidarum for offspring: a systematic review and meta-analysis. *BJOG* 2011;118:1302–13.
- Goodwin TM. Hyperemesis gravidarum. *Clin Obstet Gynecol* 2008;35:401–17.
- Verberg MF, Gillott DJ, Al-Fardan N *et al*. Hyperemesis gravidarum, a literature review. *Hum Reprod Update* 2005;11:p 527–39.
- Bottomley C, Bourne T. Management strategies for hyperemesis. *Best practice & research. Clin Obstet Gynecol* 2009;23:p 549–64.
- Matthews A, Haas DM, O'Mathúna DP *et al*. Interventions for nausea and vomiting in early pregnancy. *Cochrane Database Syst Rev* 2014; 3:CD007575.
- Reyes H, Gonzalez MC, Ribalta J *et al*. Prevalence of intrahepatic cholestasis of pregnancy in Chile. *Ann Intern Med* 1978;88:p 487–93.
- Marshall HU, Wikström Shemer E, Ludvigsson JF *et al*. Intrahepatic cholestasis of pregnancy and associated hepatobiliary disease: a population-based cohort study. *Hepatology* 2013;58:1385–91.
- Lee RH, Goodwin TM, Greenspoon J *et al*. The prevalence of intrahepatic cholestasis of pregnancy in a primarily Latina Los Angeles population. *J Perinatol* 2006;26:p527–32.
- Turunen K, Mölsä A, Helander K *et al*. Health history after intrahepatic cholestasis of pregnancy. *Acta Obstet Gynecol Scand* 2012;91:679.

40. Ropponen A, Sund R, Rikonen S *et al.* Intrahepatic cholestasis of pregnancy as an indicator of liver and biliary diseases: a population-based study. *Hepatology* 2006;43:723–8.
41. Garcia-Flores J, Canamares M, Cruceyra M *et al.* Clinical value of maternal bile acid quantification in intrahepatic cholestasis of pregnancy as an adverse perinatal outcome predictor. *Gynecol Obstet Invest* 2105;79: 222–8.
42. Geenes V, Chappell LC, Seed PT *et al.* Association of severe intrahepatic cholestasis of pregnancy with adverse pregnancy outcomes: a prospective population-based case-control study. *Hepatology* 2014;59:1482–91.
43. Fisk NM, Bye WB, Storey GN. Maternal features of obstetric cholestasis: 20 years experience at King George V Hospital. *Aust N Z J Obstet Gynaecol* 1988;28:p 172–6.
44. Bacq Y, Sapey T, Bréchet MC *et al.* Intrahepatic cholestasis of pregnancy: a French prospective study. *Hepatology* 1997;26:p358–64.
45. Turunen K, Sumanen M, Haukilahti RL *et al.* Good pregnancy outcome despite intrahepatic cholestasis. *Scand J Prim Health Care* 2010;28: 102–7.
46. Williamson C, Hems LM, Goulis DG *et al.* Clinical outcome in a series of cases of obstetric cholestasis identified via a patient support group. *BJOG* 2004;111:676.
47. Mazzella G, Rizzo N, Azzaroli F *et al.* Ursodeoxycholic acid administration in patients with cholestasis of pregnancy: effects on primary bile acids in babies and mothers. *Hepatology* 2001;33:504–8.
48. Bacq Y, Sentilhes L, Reyes HB *et al.* Efficacy of ursodeoxycholic acid in treating intrahepatic cholestasis of pregnancy: a meta-analysis. *Gastroenterology* 2012;143:1492.
49. Sibai B, Dekker G, Kupferminc M. Pre-eclampsia. *Lancet* 2005;365: 785–99.
50. ACOG Committee on Practice Bulletins-Obstetrics. ACOG practice bulletin. Diagnosis and management of preeclampsia and eclampsia. Number 33, 2002. *Obstet Gynecol* 2002;99:159.
51. Lindheimer MD, Taler SJ, Cunningham FG. Hypertension in pregnancy. *J Am Soc Hypertens* 2008;2:484–94.
52. Vigil-De Gracia P, Ortega-Paz L. Pre-eclampsia/eclampsia and hepatic rupture. *Int J Gynaecol Obstet* 2012;118:186–9.
53. Kozic JR, Benton SJ, Hutcheon JA *et al.* Abnormal liver function tests as predictors of adverse maternal outcomes in women with preeclampsia. *J Obstet Gynaecol Can* 2011;33:995–1004.
54. Thangaratinam S, Koopmans CM, Iyengar S *et al.* TIPPS (Tests in Prediction of Preeclampsia's Severity) Review Group. Accuracy of liver function tests for predicting adverse maternal and fetal outcomes in women with preeclampsia: a systematic review. *Acta Obstet Gynecol Scand* 2011;90:574–85.
55. Churchill D, Duley L, Thornton JG *et al.* Interventionist versus expectant care for severe pre-eclampsia between 24 and 34 weeks' gestation. *Cochrane Database Syst Rev* 2013;7:CD003106.
56. Koopmans CM, Bijlenga D, Groen H *et al.* Induction of labour versus expectant monitoring for gestational hypertension or mild pre-eclampsia after 36 weeks' gestation (HYPITAT): a multicentre, open-label randomised controlled trial. *Lancet* 2009;374:979–88.
57. Sibai BM. Diagnosis, controversies, and management of the syndrome of hemolysis, elevated liver enzymes, and low platelet count. *Obstet Gynecol* 2004;103:981.
58. Fitzpatrick KE, Hinshaw K, Kurinczuk JJ *et al.* Risk factors, management, and outcomes of hemolysis, elevated liver enzymes, and low platelets syndrome and elevated liver enzymes, low platelets syndrome. *Obstet Gynecol* 2014;123:618–27.
59. Martin JN Jr, Rose CH, Briery CM. Understanding and managing HELLP syndrome: the integral role of aggressive glucocorticoids for mother and child. *Am J Obstet Gynecol* 2006;195:914.
60. Sibai BM, Ramadan MK, Usta I *et al.* Maternal morbidity and mortality in 442 pregnancies with hemolysis, elevated liver enzymes, and low platelets (HELLP syndrome). *Am J Obstet Gynecol* 1993;169:1000–6.
61. Krueger KJ, Hoffman BJ, Lee WM. Hepatic infarction associated with eclampsia. *Am J Gastroenterol* 1990;85:588.
62. Alsulyman OM, Castro MA, Zuckerman E *et al.* Preeclampsia and liver infarction in early pregnancy associated with the antiphospholipid syndrome. *Obstet Gynecol* 1996;88:644.
63. Grand'Maison S, Sauv e N, Weber F *et al.* Hepatic rupture in hemolysis, elevated liver enzymes, low platelets syndrome. *Obstet Gynecol* 2012; 119:617.
64. Zarrinpar A, Farmer DG, Ghobrial RM *et al.* Liver transplantation for HELLP syndrome. *Am Surg* 2007;73:1013.
65. Martin JN Jr, Owens MY, Keiser SD *et al.* Standardized Mississippi Protocol treatment of 190 patients with HELLP syndrome: slowing disease progression and preventing new major maternal morbidity. *Hypertens Pregnancy* 2012;31:79–90.
66. Woudstra DM, Chandra S, Hofmeyr GJ *et al.* Corticosteroids for HELLP (hemolysis, elevated liver enzymes, low platelets) syndrome in pregnancy. *Cochrane Database Syst Rev* 2010, CD008148.
67. Gernsheimer T, James AH, Stasi R. How I treat thrombocytopenia in pregnancy. *Blood* 2013;121:38–47.
68. Knight M, Nelson-Piercy C, Kurinczuk JJ *et al.* UK Obstetric Surveillance System. A prospective national study of acute fatty liver of pregnancy in the UK. *Gut* 2008;57:951–6.
69. Ockner SA, Brunt EM, Cohn SM *et al.* Fulminant hepatic failure caused by acute fatty liver of pregnancy treated by orthotopic liver transplantation. *Hepatology* 1990;11:59–64.
70. Riely CL. Acute fatty liver of pregnancy. *Semin Liver Dis* 1987;7:47.
71. Moldenhauer JS, O'Brien JM, Barton JR *et al.* Acute fatty liver of pregnancy associated with pancreatitis: a life-threatening complication. *Am J Obstet Gynecol* 2004;190:502.
72. Chng CL, Morgan M, Hainsworth I *et al.* Prospective study of liver dysfunction in pregnancy in Southwest Wales. *Gut* 2002;51:876–80.
73. Goel A, Ramakrishna B, Zachariah U *et al.* How accurate are the Swansea criteria to diagnose acute fatty liver of pregnancy in predicting hepatic microvesicular steatosis? *Gut* 2011;60:138–9.
74. Treem WR, Shoup ME, Hale DE *et al.* Acute fatty liver of pregnancy, hemolysis, elevated liver enzymes, and low platelets syndrome, and long chain 3-hydroxyacyl-coenzyme A dehydrogenase deficiency. *Am J Gastroenterol* 1996;91:2293.
75. Ibdah JA, Bennett MJ, Rinaldo P *et al.* A fetal fatty-acid oxidation disorder as a cause of liver disease in pregnant women. *N Engl J Med* 1999;340:1723.
76. Spiekerkoetter U. Mitochondrial fatty acid oxidation disorders: clinical presentation of long-chain fatty acid oxidation defects before and after newborn screening. *J Inherit Metab Dis* 2010;33:527–32.
77. Ibdah JA, Dasouki MJ, Strauss AW. Long-chain 3-hydroxyacyl-CoA dehydrogenase deficiency: variable expressivity of maternal illness during pregnancy and unusual presentation with infantile cholestasis and hypocalcaemia. *J Inherit Metab Dis* 1999;22:811–4.
78. Elinav E, Ben-Dov IZ, Shapira Y *et al.* Acute hepatitis A infection in pregnancy is associated with high rates of gestational complications and preterm labor. *Gastroenterology* 2006;130:1129–34.
79. Watson JC, Fleming DW, Borella AJ *et al.* Vertical transmission of hepatitis A resulting in an outbreak in a neonatal intensive care unit. *J Infect Dis* 1993;167:567–7.
80. Urganci N, Arapoglu M, Akyildiz B *et al.* Neonatal cholestasis resulting from vertical transmission of hepatitis A infection. *Pediatr Infect Dis J* 2003;22:381–2.
81. CDC. MMWR. 2008;39:1–26. Available at <http://www.cdc.gov/mmwr>; accessed on 1 February 2015.
82. Labrique AB, Sikder SS, Krain LJ *et al.* Hepatitis E, a vaccine-preventable cause of maternal deaths. *Emerg Infect Dis* 2012;18:1401–4.
83. Patra S, Kumar A, Trivedi SS *et al.* Maternal and fetal outcomes in pregnant women with acute hepatitis E virus infection. *Ann Intern Med* 2007;147:28–33.
84. Kuniholm MH, Purcell RH, McQuillan GM *et al.* Epidemiology of hepatitis E virus in the United States: results from the Third National Health and Nutrition Examination Survey, 1988–1994. *J Infect Dis* 2009;200:48–56.
85. Renou C, Gobert V, Locher C *et al.* Prospective study of Hepatitis E Virus infection among pregnant women in France. *Virology* 2014;11:68.
86. Xu F, Sternberg MR, Kottiri BJ *et al.* Trends in herpes simplex virus type 1 and type 2 seroprevalence in the United States. *JAMA* 2006;296:964–73.
87. Norvell JP, Blei AT, Jovanovic BD *et al.* Herpes simplex virus hepatitis: an analysis of the published literature and institutional cases. *Liver Transpl* 2008;14:1428–34.
88. Levitsky J, Duddempudi AT, Lakeman FD *et al.* Detection and diagnosis of herpes simplex virus infection in adults with acute liver failure. *Liver Transpl* 2008;14:1498–504.
89. Beersma MF, Verjans GM, Metselaar HJ *et al.* Quantification of viral DNA and liver enzymes in plasma improves early diagnosis and management of herpes simplex virus hepatitis. *J Viral Hepat* 2011;18:e160–6.
90. ACOG Committee on Practice Bulletins. ACOG Practice Bulletin. Clinical management guidelines for obstetrician-gynecologists. No. 82 June 2007. Management of herpes in pregnancy. *Obstet Gynecol* 2007;109:1489–98.
91. Sheffield JS, Hollier LM, Hill JB *et al.* Acyclovir prophylaxis to prevent herpes simplex virus recurrence at delivery: a systematic review. *Obstet Gynecol* 2003;102:1396–403.

92. Andrews EB, Yankaskas BC, Cordero JF *et al*. Acyclovir in pregnancy registry: six years' experience. The Acyclovir in Pregnancy Registry Advisory Committee. *Obstet Gynecol* 1992;79:7-13.
93. Stone KM, Reiff-Eldridge R, White AD *et al*. Pregnancy outcomes following systemic prenatal acyclovir exposure: Conclusions from the international acyclovir pregnancy registry, 1984-1999. *Birth Defects Res A Clin Mol Teratol* 2004;70:201-7.
94. Navaneethan U, Lancaster E, Venkatesh PG *et al*. Herpes simplex virus hepatitis—it's high time we consider empiric treatment. *J Gastrointest Liver Dis* 2011;20:93-6.
95. Glorioso DV, Molloy PJ, Van Thiel DH *et al*. Successful empiric treatment of HSV hepatitis in pregnancy. Case report and review of the literature. *Dig Dis Sci* 1996;41:1273-5.
96. Fontana RJ. Should aciclovir be given to all patients presenting with acute liver failure of unknown etiology? *Nat Clin Pract Gastro Hep* 2008;5:298-9.
97. Edmunds WJ, Medly GF, Nokes DJ *et al*. The influence of age on the development of the hepatitis B carrier state. *Proc Biol Sci* 1993;253:197-201.
98. Pan CQ, Duan ZP, Bhamidimarri KR *et al*. An algorithm for risk assessment and intervention of mother to child transmission of hepatitis B virus. *Clin J Gastroenterol Hepatol* 2012;10:452-9.
99. Stevens CE, Beasley RP, Tsui J *et al*. Vertical transmission of hepatitis B antigen in Taiwan. *N Engl J Med* 1975;292:771-4.
100. Ngui SL, O'Connell S, Eglin RP *et al*. Low detection rate and maternal provenance of hepatitis B virus S gene mutants in cases of failed postnatal immunoprophylaxis in England and Wales. *J Infect Dis* 1997;176:1360-5.
101. Burk RD, Hwang LY, Ho GY *et al*. Outcome of perinatal hepatitis B virus exposure is dependent on maternal virus load. *J Infect Dis* 1994;170:1418-23.
102. Wiseman E, Fraser MA, Holden S *et al*. Perinatal transmission of hepatitis B virus: an Australian experience. *MJA* 2009;194:489-92.
103. Han G-R, Cao M-K, Zhao W *et al*. A prospective and open label study for the efficacy and safety of telbivudine in pregnancy for the prevention of perinatal transmission of hepatitis B virus infection. *J Hepatology* 2011;55:1215-21.
104. Zou H, Chen Y, Duan Z *et al*. A retrospective study for clinical outcome of caesarean section on perinatal transmission of hepatitis B virus in infants born to HBeAg positive mothers with chronic hepatitis. *J Viral Hepatitis* 2012;18:e18-25.
105. Hu Y, Chen J, Wen J *et al*. Effect of elective cesarean section on the risk of mother-to-child transmission of hepatitis B virus. *BMC Pregnancy Childbirth* 2013;13:119.
106. Lee SD, Lo KJ, Tsai YT *et al*. Role of caesarean section in prevention of mother-infant transmission of hepatitis B. *Lancet* 1988;2:833-4.
107. Hu Y, Chen J, Wen J *et al*. Effect of elective cesarean section on the risk of mother-to-child transmission of hepatitis B virus. *BMC Pregnancy Childbirth* 2013;13:119.
108. Pan CQ, Zou H-B, Chen Y *et al*. Cesarean section reduces perinatal transmission of HBV infection from hepatitis B surface antigen-positive women to their infants. *Clin Gastroenterol Hepatol* 2013;11:1349-55.
109. Pan CQ, Han GR, Jiang HX *et al*. Telbivudine prevents vertical transmission from HBeAg-positive women with chronic hepatitis B. *Clin Gastroenterol Hepatol* 2012;10:520-6.
110. Greenup AJ, Tan PK, Nguyen V *et al*. Efficacy and safety of tenofovir disoproxil fumarate in pregnancy to prevent perinatal transmission of hepatitis B virus. *J Hepatol* 2014;61:502-7.
111. Benboud S, Pruvost A, Coffie PA *et al*. Concentrations of tenofovir and emtricitabine in breastmilk of HIV-1 infected women in Abidjan, Cote d'Ivoire, in the ANRS 12109 TEMAA Study, Step 2. *Antimicrob Agents Chemo* 2011;vol.55:1315-7.
112. CDC. Hepatitis C FAQs for Health Professionals. Available at <http://www.cdc.gov/hepatitis/HCV/HCVfaq.htm> (accessed on 10 June 2014).
113. Pergam SA, Wang CC, Gardella CM *et al*. Pregnancy complications associated with hepatitis C: data from a 2003-2005 Washington state birth cohort. *Am J Obstet Gynecol* 2008;199:38.
114. Reddick KL, Jhaveri R, Gandhi M *et al*. Pregnancy outcomes associated with viral hepatitis. *J Viral Hepat* 2011;18:e394-8.
115. Fontaine H, Nalpas B, Carnot F *et al*. Effect of pregnancy on chronic hepatitis C: a case-control study. *Lancet* 2000;356:1328-9.
116. Paternoster DM, Santarossa C, Grella P *et al*. Viral load in HCV RNA-positive pregnant women viral load in HCV RNA-positive pregnant women. *Am J Gastroenterol* 2001;96:2751-4.
117. Alter MJ, Kruszon-Moran D, Nainan OV *et al*. The prevalence of hepatitis C virus infection in the United States, 1988 through 1994. *N Engl J Med* 1999;341:556-62.
118. Ugbebor O, Aigbirior M, Osazuwa F *et al*. The prevalence of hepatitis B and C viral infections among pregnant women. *N Am J Med Sci* 2011;3:238-41.
119. Moyer VA. U.S. Preventive Services Task Force. Screening for hepatitis C virus infection in adults: U.S. Preventive Services Task Force Recommendation Statement. *Ann Intern Med* 2013;159:349-57.
120. AASLD; IDSA; IAS-USA. Recommendations for testing, managing, and treating hepatitis C Available at: <http://www.hcvguidelines.org> (accessed on 12 January 2015).
121. Cottrell EB, Chou R, Wasson N *et al*. Reducing risk for mother-to-infant transmission of hepatitis C virus: a systematic review for the U.S. Preventive Services Task Force. *Ann Intern Med* 2013;158:109-13.
122. McIntyre PG, Tosh K, McGuire W. Caesarean section versus vaginal delivery for preventing mother to infant hepatitis C virus transmission. *Cochrane Database Syst Rev* 2006, CD005546.
123. Westbrook RH, Yeoman AD, Kriese S *et al*. Outcomes of pregnancy in women with autoimmune hepatitis. *J Autoimmun* 2012;38:J239-44.
124. Schramm C, Herkel J, Beuers U *et al*. Pregnancy in autoimmune hepatitis: outcome and risk factors. *Am J Gastroenterol* 2006;101:556-60.
125. Werner M. Autoimmune hepatitis among fertile women: strategies during pregnancy and breastfeeding? *Scand J Gastroenterol* 2007;42:986-91.
126. Manns MP, Czaja AJ, Gorham JD *et al*. Diagnosis and management of autoimmune hepatitis. *American Association for the Study of Liver Diseases. Hepatology* 2010;51:2193-213.
127. Lamers MM, van Oijen MG, Pronk M *et al*. Treatment options for autoimmune hepatitis: a systematic review of randomized controlled trials. *J Hepatol* 2010;53:191-8.
128. Hviid A, Mølgaard-Nielsen D. Corticosteroid use during pregnancy and risk of orofacial clefts. *CMAJ* 2011;183:796-804.
129. Czaja AJ, Freese DK. Diagnosis and treatment of autoimmune hepatitis. *Hepatology* 2002;36:479-97.
130. Westbrook RH, Yeoman AD, Kriese S *et al*. Outcomes of pregnancy in women with autoimmune hepatitis. *J Autoimmun* 2012;38:239-44.
131. Terrabuio DR, Abrantes-Lemos CP, Carrilho FJ *et al*. Follow-up of pregnant women with autoimmune hepatitis: the disease behavior along with maternal and fetal outcomes. *J Clin Gastroenterol* 2009;43:350-6.
132. Efe C, Ozaslan E, Purnak T. Outcome of pregnancy in patients with autoimmune hepatitis/primary biliary cirrhosis overlap syndrome: a report of two cases. *Clin Res Hepatol Gastroenterol* 2011;35:687-9.
133. Heneghan MA, Norris SM, O'Grady JG *et al*. Management and outcome of pregnancy in autoimmune hepatitis. *Gut* 2001;48:97-102.
134. Powell EE, Molloy D. Successful *in vitro* fertilization and pregnancy in a patient with autoimmune chronic active hepatitis and cirrhosis. *J Gastroenterol Hepatol* 1995;10:233-5.
135. Lee MG, Hanchard B, Donaldson EK *et al*. Pregnancy in chronic active hepatitis with cirrhosis. *J Trop Med Hyg* 1987;90:245-8.
136. Steven MM, Buckley JD, Mackay IR. Pregnancy in chronic active hepatitis. *Q J Med* 1979;48:519-31.
137. Akbari M, Shah S, Velayos FS *et al*. Systematic review and meta-analysis on the effects of thiopurines on birth outcomes from female and male patients with inflammatory bowel disease. *Inflamm Bowel Dis* 2013;19:15-22.
138. Cleary BJ, Källén B. Early pregnancy azathioprine use and pregnancy outcomes. *Birth Defects Res A Clin Mol Teratol* 2009;85:647-54.
139. Østensen M, Förger F. How safe are anti-rheumatic drugs during pregnancy? *Curr Opin Pharmacol* 2013;13:470-5.
140. Casanova MJ, Chaparro M, Domènech E *et al*. Safety of thiopurines and anti-TNF- α drugs during pregnancy in patients with inflammatory bowel disease. *Am J Gastroenterol* 2013;108:433-40.
141. Hutson JR, Matlow JN, Moretti ME *et al*. The fetal safety of thiopurines for the treatment of inflammatory bowel disease in pregnancy. *J Obstet Gynaecol* 2013;33:1-8.
142. Coelho J, Beauberger L, Colombel JF *et al*. Pregnancy outcome in patients with inflammatory bowel disease treated with thiopurines: cohort from the CESAME Study. *Gut* 2011;60:198-203.
143. Whelton MJ, Sherlock S. Pregnancy in patients with hepatic cirrhosis. Management and outcome. *Lancet* 1968;2:995-9.
144. Trivedi PJ, Kumagi T, Al-Harthi N *et al*. Good maternal and fetal outcomes for pregnant women with primary biliary cirrhosis. *Clin Gastroenterol Hepatol* 2014;12:1179-85.
145. Goh SK, Gull SE, Alexander GJ. Pregnancy in primary biliary cirrhosis complicated by portal hypertension: report of a case and review of the literature. *BJOG* 2001;108:760-2.

146. Lindor KD, Gershwin ME, Poupon R *et al.* Primary biliary cirrhosis. *Hepatology* 2009;50:291–308.
147. Efe C, Kahramanoğlu-Aksoy E, Yilmaz B *et al.* Pregnancy in women with primary biliary cirrhosis. *Autoimmun Rev* 2014;13:931–5.
148. Rudi J, Schönig T, Stremmel W. Therapy with ursodeoxycholic acid in primary biliary cirrhosis in pregnancy. *Z Gastroenterol* 1996;34:188–91.
149. Carey EJ, White P. Ursodeoxycholic acid for intrahepatic cholestasis of pregnancy: good for the mother, not bad for the baby. *Evid Based Med* 2013;18:e55.
150. Vitek L, Zelenková M, Brůha R. Safe use of ursodeoxycholic acid in a breast-feeding patient with primary biliary cirrhosis. *Dig Liver Dis* 2010;42:911–2.
151. Sinha S, Taly AB, Prashanth LK *et al.* Successful pregnancies and abortions in symptomatic and asymptomatic Wilson's disease. *J Neurol Sci* 2004;217:37–40.
152. Malik A, Khawaja A, Sheikh L. Wilson's disease in pregnancy: case series and review of literature. *BMC Res Notes* 2013;6:421.
153. Sternlieb I. Wilson's disease and pregnancy. *Hepatology* 2000;31:531–2.
154. Wiggelinkhuizen M, Tilanus ME, Bollen CW *et al.* Systematic review: clinical efficacy of chelator agents and zinc in the initial treatment of Wilson disease. *Aliment Pharmacol Ther* 2009;29:947–58.
155. Roberts EA, Schilsky ML. Diagnosis and treatment of Wilson disease: an update. *Hepatology* 2008;47:2089–111.
156. Masciullo M, Modoni A, Bianchi ML *et al.* Positive outcome in a patient with Wilson's disease treated with reduced zinc dosage in pregnancy. *Eur J Obstet Gynecol Reprod Biol* 2011;159:237–8.
157. Brewer GJ, Johnson VD, Dick RD *et al.* Treatment of Wilson's disease with zinc. XVII: treatment during pregnancy. *Hepatology* 2000;31:364–70.
158. Hartard C, Kunze K. Pregnancy in a patient with Wilson's disease treated with D-penicillamine and zinc sulfate. A case report and review of the literature. *Eur Neurol* 1994;34:337–40.
159. Hanukoglu A, Curiel B, Berkowitz D *et al.* Hypothyroidism and dys-hormonogenesis induced by D-penicillamine in children with Wilson's disease and healthy infants born to a mother with Wilson's disease. *J Pediatr* 2008;153:864–6.
160. Pinter R, Hogge WA, McPherson E. Infant with severe penicillamine embryopathy born to a woman with Wilson disease. *Am J Med Genet A* 2004;128A:294–8.
161. Yalaz M, Aydogdu S, Ozgenc F *et al.* Transient fetal myelosuppressive effect of D-penicillamine when used in pregnancy. *Minerva Pediatr* 2003;55:625–8.
162. Martínez-Frías ML, Rodríguez-Pinilla E, Bermejo E *et al.* Prenatal exposure to penicillamine and oral clefts: case report. *Am J Med Genet* 1998;76:274–5.
163. Russell MA, Craigo SD. Cirrhosis and portal hypertension in pregnancy. *Sem Perinatol* 1998;22:156–65.
164. Pajor A, Lehoczy D. Pregnancy in liver cirrhosis. Assessment of maternal and fetal risks in eleven patients and review of the management. *Gynecol Obstet Invest* 1994;38:45–50.
165. Shaheen AA, Myers RP. The outcomes of pregnancy in patients with cirrhosis: a population-based study. *Liver Int* 2010;30:275–83.
166. Rasheed SM, Abdel Monem AM, Abd Allah AH *et al.* Prognosis and determinants of pregnancy outcome among patients with post-hepatitis liver cirrhosis. *Int J Gynaecol Obstet* 2013;121:247–51.
167. Pajor A, Lehoczy D. Pregnancy and extrahepatic portal hypertension. Review and report on the management. *Gynecol Obstet Invest* 1990;30:193–7.
168. Britton RC. Pregnancy and esophageal varices. *Am J Surg* 1982;143:421–5.
169. Sandhu BS, Sanyal AJ. Pregnancy and liver disease. *Gastro Clin North Am* 2003;32:407–36.
170. Chaudhuri K, Tan EK, Biswas A. Successful pregnancy in a woman with liver cirrhosis complicated by recurrent variceal bleeding. *J Obstet Gynaecol* 2012;32:490–1.
171. Lodato F, Cappelli A, Montagnani M *et al.* Transjugular intrahepatic portosystemic shunt: a case report of rescue management of unrestrainable variceal bleeding in a pregnant woman. *Dig Liver Dis* 2008;40:387–90.
172. Fair J, Klein AS, Feng T *et al.* Intrapartum orthotopic liver transplantation with successful outcome of pregnancy. *Transplantation* 1990;50:534–5.
173. Friedel D, Stavropoulos S, Iqbal S *et al.* Gastrointestinal endoscopy in the pregnant woman. *World J Gastrointest Endosc* 2014;6:156–67.
174. Ghidirim G, Mishin I, Dolgih A *et al.* Prophylactic endoscopic band ligation of esophageal varices during pregnancy. *J Gastrointest Liver Dis* 2008;17:236–7.
175. Zeeman GG, Moise KJ Jr. Prophylactic banding of severe esophageal varices associated with liver cirrhosis in pregnancy. *Obstet Gynecol* 1999;94:842.
176. Starkel P, Horsmans Y, Geubel A. Endoscopic band ligation: a safe technique to control bleeding esophageal varices in pregnancy. *Gastrointest Endosc* 1998;48:212–4.
177. Schwethelm B, Margolis LH, Miller C *et al.* Risk status and pregnancy outcome among Medicaid recipients. *Am J Prev Med* 1989;5:157–63.
178. Heriot JA, Steven CM, Sattin RS. Elective forceps delivery and extradural anaesthesia in a primigravida with portal hypertension and oesophageal varices. *Br J Anaesth* 1996;76:325–7.
179. Cundy TE, O'Grady JG, Williams R. Recovery of menstruation and pregnancy after liver transplantation. *Gut* 1990;31:337–8.
180. McKay DB, Josephson MA, Armenti VT *et al.* Reproduction and transplantation: report on the AST Consensus Conference on Reproductive Issues and Transplantation. *Am J Transplant* 2005;5:1592–9.
181. Deshpande NA, James NT, Kucirka LM *et al.* Pregnancy outcomes of liver transplant recipients: a systematic review and meta-analysis. *Liver Transpl* 2012;18:621–9.
182. Armenti VT, Radomski JS, Moritz MJ *et al.* Report from the National Transplantation Pregnancy Registry (NTPR): outcomes of pregnancy after transplantation. *Clin Transpl* 2005, 69–83.
183. Christopher V, Al-Chalabi T, Richardson PD *et al.* Pregnancy outcome after liver transplantation: a single-center experience of 71 pregnancies in 45 recipients. *Liver Transpl* 2006;12:1138–43.
184. Dei Malatesta MF, Rossi M, Rocca B *et al.* Pregnancy after liver transplantation: report of 8 new cases and review of the literature. *Transpl Immunol* 2006;15:297–302.
185. Nagy S, Bush MC, Berkowitz R *et al.* Pregnancy outcome in liver transplant recipients. *Obstet Gynecol* 2003;102:121–8.
186. Bar OzB, Hackman R, Einarson T *et al.* Pregnancy outcome after cyclosporine therapy during pregnancy: a meta-analysis. *Transplantation* 2001;71:1051–5.
187. Paziana K, Del Monaco M, Cardonick E *et al.* Cyclosporin use during pregnancy. *Drug Saf* 2013;36:279–94.
188. Grimer M. Caring for Australians with Renal Impairment (CARI). The CARI guidelines. Calcineurin inhibitors in renal transplantation: pregnancy, lactation and calcineurin inhibitors. *Nephrology* 2007;12:S98–105.
189. Ducarme G, Théron-Gérard L, Duvoux C *et al.* Pregnancy after liver transplantation with tacrolimus. *Eur J Obstet Gynecol Reprod Biol* 2007;133:249–50.
190. Jain AB, Reyes J, Marcos A *et al.* Pregnancy after liver transplantation with tacrolimus immunosuppression: a single center's experience update at 13 years. *Transplantation* 2003;76:827–32.
191. Kainz A, Harabacz I, Cowrick IS *et al.* Review of the course and outcome of 100 pregnancies in 84 women treated with tacrolimus. *Transplantation* 2000;70:1718–21.
192. Rayes N, Neuhaus R, David M *et al.* Pregnancies following liver transplantation—how safe are they? A report of 19 cases under cyclosporine A and tacrolimus. *Clin Transplant* 1998;12:396–400.
193. Margoles HR, Gomez-Lobo V, Veis JH *et al.* Successful maternal and fetal outcome in a kidney transplant patient with everolimus exposure throughout pregnancy: a case report. *Transplant Proc* 2014;46:281–3.
194. Carta P, Caroti L, Zanazzi M. Pregnancy in a kidney transplant patient treated with everolimus. *Am J Kidney Dis* 2012;60:329.
195. Veroux M, Corona D, Veroux P. Pregnancy under everolimus-based immunosuppression. *Transpl Int* 2011;24:e115–7.
196. Guardia O, Rial Mdel C, Casadei D. Pregnancy under sirolimus-based immunosuppression. *Transplantation* 2006;81:636.
197. Kim M, Rostas S, Gabardi S. Mycophenolate fetal toxicity and risk evaluation and mitigation strategies. *Am J Transplant* 2013;13:1383–9.
198. Lin AE, Singh KE, Strauss A *et al.* An additional patient with mycophenolate mofetil embryopathy: cardiac and facial analyses. *Am J Med Genet A* 2011;155A:748–56.
199. Klieger-Grossmann C, Chitayat D, Lavign S *et al.* Prenatal exposure to mycophenolate mofetil: an updated estimate. *J Obstet Gynaecol Can* 2010;32:794–7.
200. Merlob P, Stahl B, Klinger G. Tetrad of the possible mycophenolate mofetil embryopathy: a review. *Reprod Toxicol* 2009;28:105–8.
201. Moretti ME, Lee A, Ito S. Which drugs are contraindicated during breastfeeding? Practice guidelines. *Can Fam Physician* 2000;46:1753–7.
202. Zheng S, Easterling TR, Hays K *et al.* Tacrolimus placental transfer at delivery and neonatal exposure through breast milk. *Br J Clin Pharmacol* 2013;76:988–96.

203. Armenti VT, Moritz MJ, Davison JM. Breastfeeding and tacrolimus: is it a reasonable approach? *Expert Rev Clin Immunol* 2013;9:623–6.
204. Bramham K, Chusney G, Lee J *et al*. Breastfeeding and tacrolimus: serial monitoring in breast-fed and bottle-fed infants. *Clin J Am Soc Nephrol* 2013;8:563–7.
205. Gouraud A, Bernard N, Millaret A *et al*. Follow-up of tacrolimus breastfed babies. *Transplantation* 2012;94:e38–40.
206. Moretti ME, Sgro M, Johnson DW *et al*. Cyclosporine excretion into breast milk. *Transplantation* 2003;75:2144–6.
207. Osadchy A, Koren G. Cyclosporine and lactation: when the mother is willing to breastfeed. *Ther Drug Monit* 2011;33:147–8.
208. Munoz-Flores-Thiagarajan KD, Easterling T, Davis C *et al*. Breastfeeding by a cyclosporine-treated mother. *Obstet Gynecol* 2001;97:816–8.

APPENDIX

Appendix search terms:

- Pregnancy
- Physiology pregnancy
- Liver tests pregnancy
- Transaminitis pregnancy
- Ultrasound
- Computed tomography pregnancy
- Magnetic resonance imaging pregnancy
- Teratogenesis imaging
- Liver biopsy pregnancy
- Endoscopy pregnancy
- Anesthesia pregnancy
- Opiate pregnancy
- Meperidine pregnancy
- Propofol
- ERCP pregnancy
- Pancreatitis Pregnancy
- Cholelithiasis/cholecystitis pregnancy
- Laparoscopy pregnancy
- Liver masses pregnancy
- Hemangioma
- Adenoma pregnancy
- Hormones and adenoma
- Hepatitis B pregnancy
- Perinatal hepatitis B
- Transmission hepatitis B
- Tenofovir
- Cesarean and hepatitis
- Breastfeeding and hepatitis
- Hepatitis C and pregnancy,
- HCV vertical transmission,
- HCV breastfeeding,
- HCV delivery,
- HCV c-section,
- Hyperemesis gravidarum,
- Intrahepatic cholestasis of pregnancy,
- Ursodeoxycholic acid,
- Preeclampsia,
- Eclampsia,
- HELP
- Transplant,
- Hepatic infarction,
- Acute fatty liver disease of pregnancy
- Fulminant hepatic failure
- Breastfeeding, lactation

- Fertility
- Contraception
- Viral hepatitis- hepatitis A, hepatitis E, herpes simplex virus, cytomegalovirus, Epstein-Barr virus, adenovirus
- Acyclovir
- Cirrhosis
- Autoimmune hepatitis, primary biliary cirrhosis, primary sclerosing cholangitis, Wilson's disease, Hereditary hemochromatosis
- Varices, ascites, hepatic encephalopathy
- Endoscopy, band ligation, screening
- Liver transplantation
- Ursodeoxycholic acid, cholestyramine, octreotide
- Azathioprine, tacrolimus, cyclosporine, prednisone, mycophenolate mofetil, 6-mercaptopurine
- Zinc, penicillamine, trientine
- Caesarean section.